



PATIENT PRESENTING CLINICAL SIGNS

Sugar Man Lawrence Coughing since the last 2 weeks, raspy breathing. Had fever of 40 degrees Celsius Responded well to Pred and Doxy
 Abnormal PE/Chem/CBC/UA Results: CBC shows mild neutrophilia, monocytosis Chem WNL T4 normal

SPECIES

Feline **RADIOGRAPHIC STUDY OF THE THORAX**

Radiographs of the thorax in three imaging planes are provided for review.

BREED RADIOGRAPHIC FINDINGS

DSH The surrounding bony structures are within normal limits.
 The extrathoracic soft tissues present homogeneous without abnormalities.

SEX The heart is of normal size and shape, there is no evidence of cardiac chamber or vascular enlargement.
 The pulmonary vasculature is within normal limits.

MN The trachea is normal in diameter and presents the anticipated course. The luminal outline of the trachea is smooth.

AGE Generalized moderate thickening of the bronchial walls is appreciated.

9 Years The lung parenchyma presents the expected architecture and opacity; the intrapulmonary vascular branching is seen up to the third order lung vessels.

INTERPRETED BY

The diaphragm is well delineated with even surface and the expected mild cranial bulging of the diaphragmatic cupola.

Sebastian Schaub, DVM
 Dr. med. vet. DipECVDI

RADIOGRAPHIC DIAGNOSIS

HOSPITAL NAME

- Bronchial lung pattern
- No evidence of air trapping

Balmy Beach Pet Hospital

INTERPRETATION OF THE FINDINGS & FURTHER RECOMMENDATIONS

REFERRING VET

The radiographic changes are suggestive for feline bronchial disease ("feline asthma") – commonly primary allergic in origin ± bacterial superinfection. Primary infectious causes – such as viral, parasitic, bacterial, Mycoplasma – are considerations and the odds are increased given the history of fever. In very few cases, the bronchial pattern can be a sequela to bronchial carcinoma. Bronchoscopy including BAL can be used as advanced diagnostic tools, if clinical signs are refractory to therapy or deteriorate again.

INVOICE

58891

DATE

6-19-23



PATIENT

Sugar Man Lawrence

SPECIES

Feline

BREED

DSH

SEX

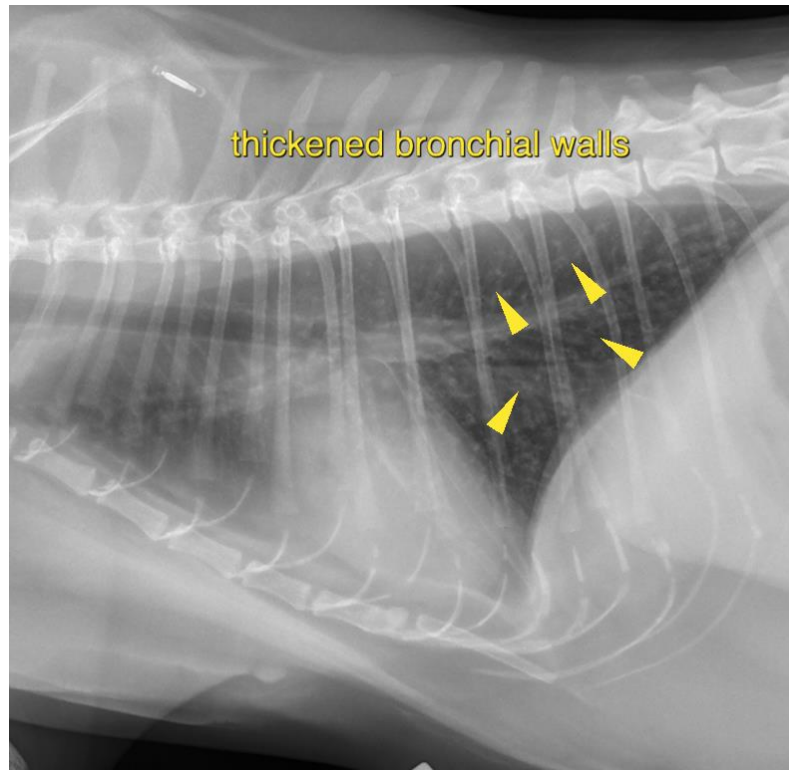
MN

AGE

9 Years

INTERPRETED BY

Sebastian Schaub, DVM
Dr. med. vet. DipECVCI



HOSPITAL NAME

Balmy Beach Pet
Hospital

REFERRING VET

Dr. Singh

INVOICE

58891

DATE

6-19-23

The information and recommendations provided are based on the images presented by the referring veterinarian/sonographer. No evaluation can be communicated regarding pathology that was not visible in the image/video clips provided.

Thank you for this referral. If the clinical or image interpretation does not parallel your findings or if I can be of any further assistance please contact me.

Sebastian Schaub, Sebastian Schaub, DVM, Dr. med. vet. DipECVCI
info@sonopath.com