



PATIENT

Trixie Brocklebank

PRESENTING CLINICAL SIGNS

dog had spinal surgery (herniated disc repair) at T11-T12 last December . two days ago, she had a sudden onset of weak left hind leg
Abnormal PE/Chem/CBC/UA Results: unremarkable

SPECIES

Canine

RADIOGRAPHIC STUDY OF THE LUMBAR SPINE AND STIFLE JOINT

Radiographs of the lumbar spine in a lateral view and mediolateral projections of the stifle joints are provided for review.

BREED

Dachshund Mix

RADIOGRAPHIC FINDINGS

The lateral view of the lumbar spine is moderately rotated. Mineralized material is superimposed on the neuroforamen L2/L3 as well as the ventral aspect of the respective neuroforamina.

SEX

Female Spayed

Both stifle joints present smooth osseous margins. The right stifle joint presents without evidence of intracapsular swelling. The mediolateral view of the left stifle joint is moderately rotated, the intracapsular soft tissue volume is increased.

AGE

5 Years

RADIOGRAPHIC DIAGNOSIS

- Suspect articular swelling left stifle joint
- Chondroid disc degeneration L2/L3 with mineralized material superimposed on the neuroforamen L2/L3

INTERPRETED BY

Sebastian Schaub, DVM
Dr. med. vet. DipECVDI

INTERPRETATION OF THE FINDINGS & FURTHER RECOMMENDATIONS

The rotation of the left stifle joint is limiting diagnostic value for assessment for potential effusion and the suspected effusion might be a sequela to superimposition with normal anatomy. If effusion is present – this can be traumatic, degenerative or inflammatory in origin. Check clinically if there is evidence of articular swelling of the left stifle joint and if a positive drawer signs/tibial compression test are present.

HOSPITAL NAME

St. Catherine's Animal Hospital

The mineralized disc material level L2/L3 can indicate disc material within the vertebral canal that might be associated with compressive myelopathy.

REFERRING VET

Dr. Boctor

INVOICE

52507

DATE

6-18-22



PATIENT

Trixie Brocklebank

SPECIES

Canine

BREED

Dachshund Mix

SEX

Female Spayed

AGE

5 Years

INTERPRETED BY

Sebastian Schaub, DVM
Dr. med. vet. DipECVDI

HOSPITAL NAME

St. Catherine's Animal
Hospital

REFERRING VET

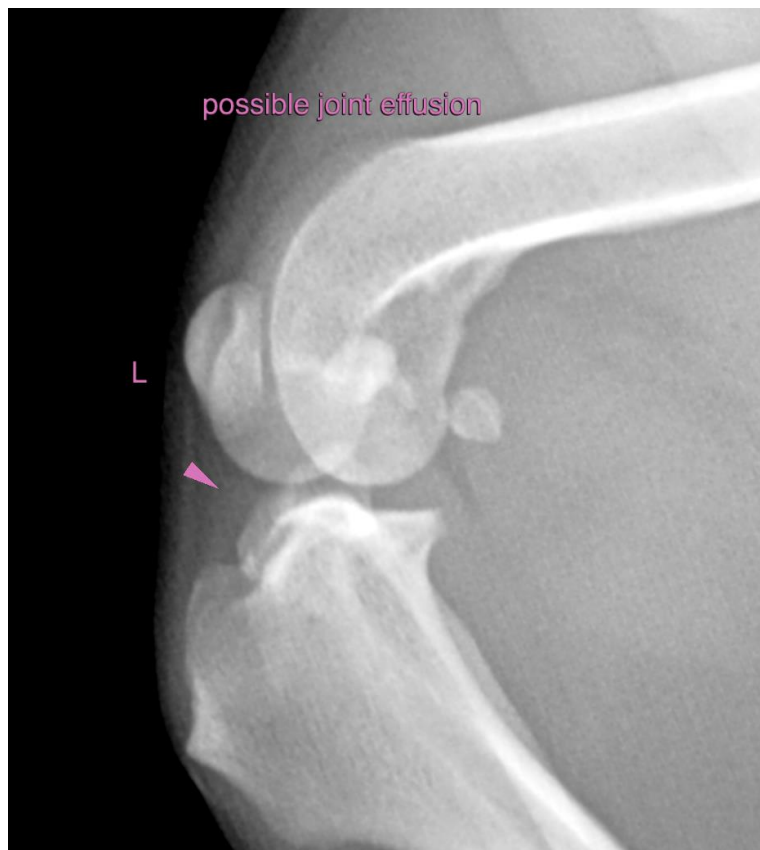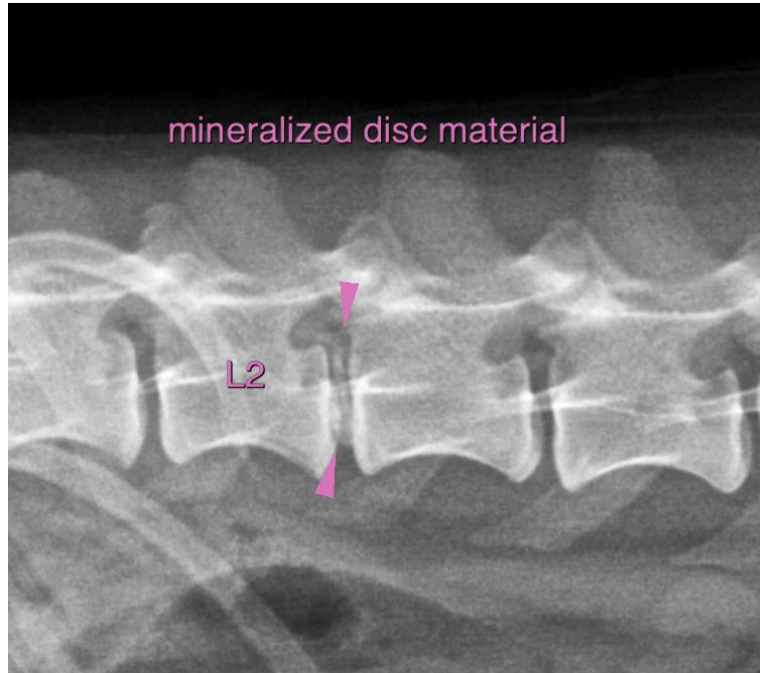
Dr. Boctor

INVOICE

52507

DATE

6-18-22





PATIENT

Trixie Brocklebank

SPECIES

Canine

The information and recommendations provided are based on the images presented by the referring veterinarian/sonographer. No evaluation can be communicated regarding pathology that was not visible in the image/video clips provided.

BREED

Dachshund Mix

Thank you for this referral. If the clinical or image interpretation does not parallel your findings or if I can be of any further assistance please contact me.

SEX

Female Spayed

Sebastian Schaub, Sebastian Schaub, DVM, Dr. med. vet. DipECVDI
sebast.schaub@gmail.com

AGE

5 Years

INTERPRETED BY

Sebastian Schaub, DVM
Dr. med. vet. DipECVDI

HOSPITAL NAME

St. Catherine's Animal
Hospital

REFERRING VET

Dr. Boctor

INVOICE

52507

DATE

6-18-22