SonoPath Teleradiology

EDUCATIONAL TELECONSULTATION SERVICES™

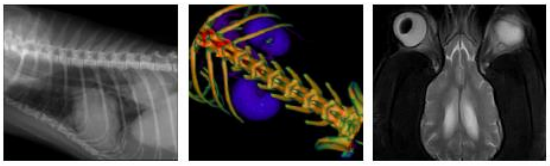

SonoPath.com
1-800-838-4268 info@sonopath.com

PATIENT

Diesel Litral

SPECIES

Canine

BREED

Australian Cattle Dog

SEX

MN

AGE

6 Years, 6 Months

INTERPRETED BY

Sebastian Schaub, DVM
Dr. med. vet. DipECVDI

HOSPITAL NAME

South Bay Animal Hospital + Emergency

REFERRING VET

Ravinder Atwal, DVM, CCRP

INVOICE

52508

DATE

6-18-22

PRESENTING CLINICAL SIGNS

Patient presents for evaluation of a new nasal mass and moderate epistaxis that has been non-responsive to steroids and antibiotics from pDVM. Prior nasal CT read in November (right sided destructive rhinitis with mild hyperostosis) and biopsy of that mass displayed a diagnosis of severe, chronic, lymphoplasmacytic suppurative and mildly granulomatous rhinitis. A head and thorax series are submitted for review.
Abnormal PE/Chem/CBC/UA Results: NSF

COMPUTED TOMOGRAPHY OF THE SKULL AND THORAX

A high resolution pre- and post-contrast CT study of the skull and a post-contrast CT study of the thorax are provided for review.

COMPUTED TOMOGRAPHIC FINDINGS

Skull

The tooth elements 107, 207, 308 and 408 are absent. Moderate abrasion of the crowns of the incisor and canine teeth is appreciated.

In the right nasal cavity, advanced destruction of the nasal conchal & turbinate structures is appreciated, resulting in an 'empty nose'. A moderate amount of non-contrast enhancing irregular soft tissue material is attached to the mucosal lining of the right nasal cavity & frontal sinus. The osseous lining of the caudodorsal aspect of the right nasal cavity and the right frontal sinus present mild to moderate hyperostosis. A defect is seen in the dorsal aspect of the right frontal sinus measuring 10 mm in diameter. The cribriform plate is intact.

Both temporomandibular joints present congruent joint spaces with even subchondral bone surfaces and are considered within normal limits.

Both tympanic bullae are aerated, the mucosal lining is not seen, the bony wall is smooth and thin. The external ear canals are within normal limits.

The brain presents no deviation from normal anatomy and symmetry. The brain parenchyma is homogeneous and within normal limits for attenuation and distribution of contrast enhancement. The ventricular system is non-dilated and symmetric.

The right mandibular lymph nodes are prominent.

Thorax

Multiple intervertebral discs of the thoracic spine are mildly protruding into the vertebral canal.

The sternal, cranial mediastinal and tracheobronchial lymph nodes are small elongated with a normal short-to-long-axis-ratio is < 0.5, the attenuation and contrast enhancement pattern is uniform and considered within normal limits.

The cardiovascular structures including the pulmonary vasculature are within normal limits.

The bronchial tree presents with regular branching and tapers uniformly towards the periphery as expected, the bronchial walls are thin and smooth. The bronchus-to-artery ratio is within normal limits.

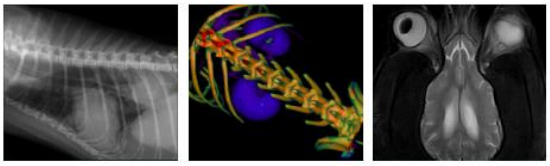

SonoPath.com
1-800-838-4268 info@sonopath.com

PATIENT

Diesel Litral

SPECIES

Canine

BREED

Australian Cattle Dog

SEX

MN

AGE

6 Years, 6 Months

INTERPRETED BY

Sebastian Schaub, DVM
Dr. med. vet. DipECVDI

HOSPITAL NAME

South Bay Animal Hospital + Emergency

REFERRING VET

Ravinder Atwal, DVM, CCRP

INVOICE

52508

DATE

6-18-22

The lung parenchyma presents the expected architecture and attenuation behavior with randomly distributed mild punctuate mineralization of the lung parenchyma.

Small incidental gas pockets are seen within the esophageal lumen, there is no evidence of abnormal dilation.

COMPUTED TOMOGRAPHIC DIAGNOSIS

- Possible preceding trepanation of the right frontal sinus
- Right sided chronic destructive rhinitis with hyperostosis of the osseous lining
- Lymphadenopathy right mandibular lymph nodes
- Multiple absent teeth
- Pulmonary osteomas
- No evidence of pulmonary metastatic disease

INTERPRETATION OF THE FINDINGS & FURTHER RECOMMENDATIONS

The findings are consistent with right sided unilateral destructive rhinitis with hyperostosis of the surrounding osseous structures. The findings are compatible with mycotic rhinitis (Aspergillus is most common). Rhinoscopy including sampling for culture and histopathology (detection of fungi microscopically is more straightforward than with culture in many cases) is recommended. Local antimycotic therapy appears indicated, the cribriform plate is intact.

There are no signs for neoplastic disease.

Secondary reactive hyperplasia of the right mandibular lymph nodes.

SonoPath Teleradiology

EDUCATIONAL TELECONSULTATION SERVICES™

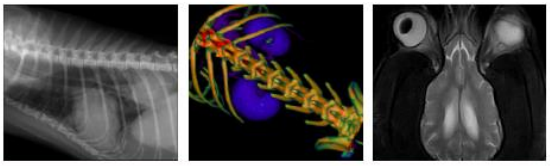

SonoPath.com
1-800-838-4268 info@sonopath.com

PATIENT

Diesel Litral

SPECIES

Canine

BREED

Australian Cattle Dog

SEX

MN

AGE

6 Years, 6 Months

INTERPRETED BY

Sebastian Schaub, DVM
Dr. med. vet. DipECVDI

HOSPITAL NAME

South Bay Animal Hospital + Emergency

REFERRING VET

Ravinder Atwal, DVM, CCRP

INVOICE

52508

DATE

6-18-22

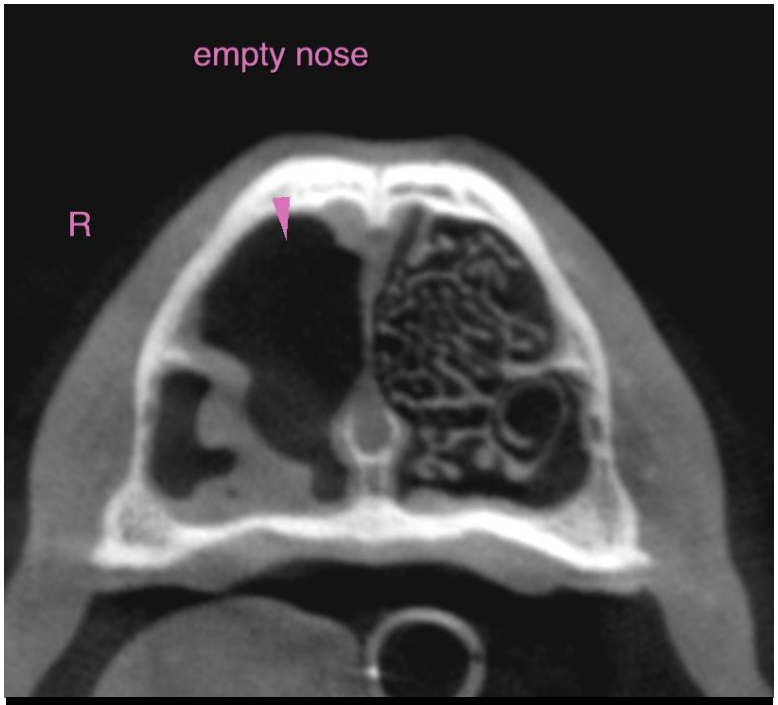

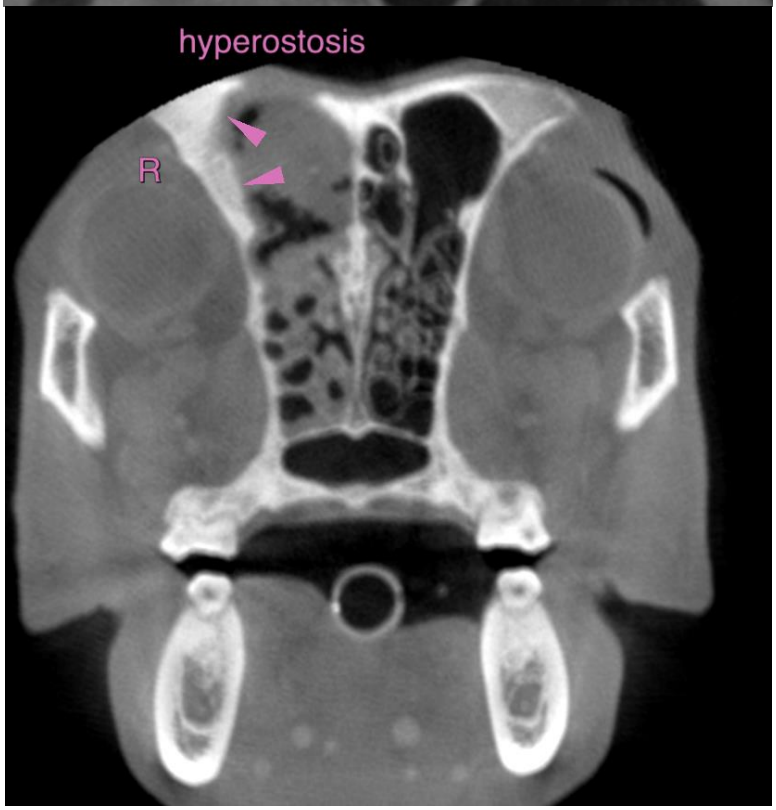

SonoPath Teleradiology

EDUCATIONAL TELECONSULTATION SERVICES™

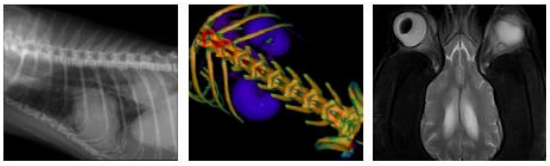

SonoPath.com
1-800-838-4268 info@sonopath.com

PATIENT

Diesel Litral

SPECIES

Canine

BREED

Australian Cattle Dog

SEX

MN

AGE

6 Years, 6 Months

INTERPRETED BY

Sebastian Schaub, DVM
Dr. med. vet. DipECVDI

HOSPITAL NAME

South Bay Animal Hospital + Emergency

REFERRING VET

Ravinder Atwal, DVM, CCRP

INVOICE

52508

DATE

6-18-22

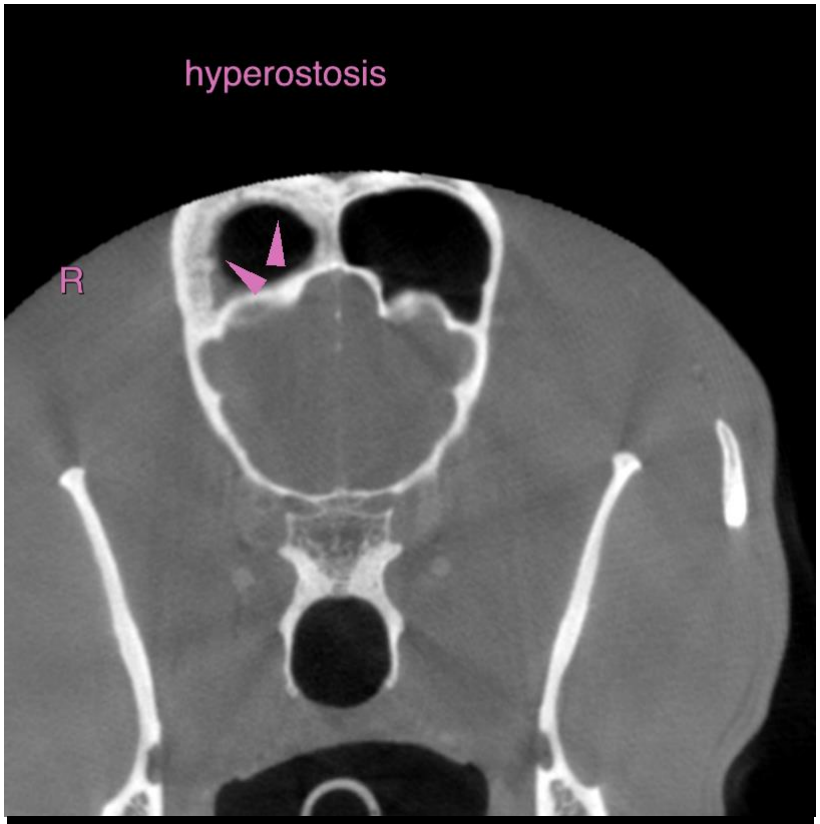

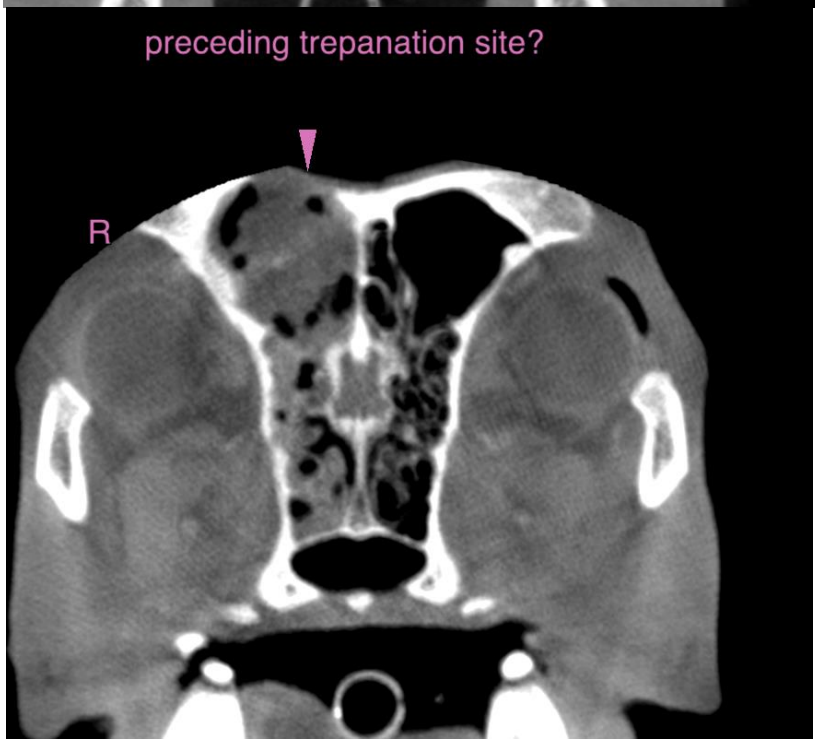

SonoPath Teleradiology

EDUCATIONAL TELECONSULTATION SERVICES™

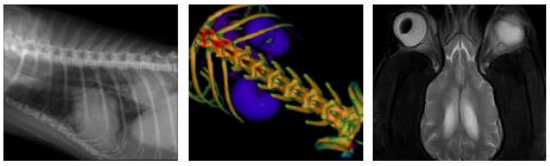

SonoPath.com
1-800-838-4268 info@sonopath.com

PATIENT

Diesel Litral

SPECIES

Canine

BREED

Australian Cattle Dog

SEX

MN

AGE

6 Years, 6 Months

INTERPRETED BY

Sebastian Schaub, DVM
Dr. med. vet. DipECVDI

HOSPITAL NAME

South Bay Animal Hospital + Emergency

REFERRING VET

Ravinder Atwal, DVM, CCRP

INVOICE

52508

DATE

6-18-22

The information and recommendations provided are based on the images presented by the referring veterinarian/sonographer. No evaluation can be communicated regarding pathology that was not visible in the image/video clips provided.

Thank you for this referral. If the clinical or image interpretation does not parallel your findings or if I can be of any further assistance please contact me.

Sebastian Schaub, Sebastian Schaub, DVM, Dr. med. vet. DipECVDI
sebast.schaub@gmail.com