



**PATIENT**

Ivy Midak

**PRESENTING CLINICAL SIGNS**

G1-G2 heart murmur with no clinical symptoms

**RADIOGRAPHIC STUDY OF THE THORAX**

**SPECIES**

Canine

Radiographs of the thorax in three imaging planes are provided for review.

**RADIOGRAPHIC FINDINGS**

The surrounding bony structures are within normal limits.

**BREED**

American Bull Dog

The extrathoracic soft tissues present homogeneous without abnormalities.

The heart is of normal size and shape, there is no evidence of cardiac chamber or vascular enlargement. The pulmonary vasculature is within normal limits.

**SEX**

F

The cranial mediastinum presents the expected soft tissue opacity. The mediastinal width is less than twice the width of the vertebral column at the same level.

The trachea is normal in diameter and presents the anticipated course. The luminal outline of the trachea is smooth.

**AGE**

15 Months

The bronchial tree presents with thin walls and tapers uniformly towards the periphery as expected.

The lung parenchyma presents the expected architecture and opacity; the intrapulmonary vascular branching is seen up to the third order lung vessels.

The diaphragm is well delineated with even surface and the expected mild cranial bulging of the diaphragmatic cupola.

In the stomach multiple mild mineral opaque bodies of variable size are appreciated.

**INTERPRETED BY**

Sebastian Schaub, DVM  
Dr. med. vet. DipECVDI

**RADIOGRAPHIC DIAGNOSIS**

- Possible gastric foreign bodies
- Structural normal thorax

**HOSPITAL NAME**

Truscott Animal Hospital

**REFERRING VET**

Dr. Medhat Meawad

**INTERPRETATION OF THE FINDINGS & FURTHER RECOMMENDATIONS**

The tubular structures in the stomach can represent some tubular plastic material as well as normal ingested osseous material – check for history of potential foreign body ingestion and the fed diet.

**INVOICE**

52512

The cardiovascular structures present without abnormalities, however a cardiac echo is recommended as advanced imaging modality for assessment of the heart murmur.

**DATE**

6-17-22



**PATIENT**

Ivy Midak

**SPECIES**

Canine

**BREED**

American Bull Dog

**SEX**

F

**AGE**

15 Months

**INTERPRETED BY**

Sebastian Schaub, DVM  
Dr. med. vet. DipECVDI

**HOSPITAL NAME**

Truscott Animal  
Hospital

**REFERRING VET**

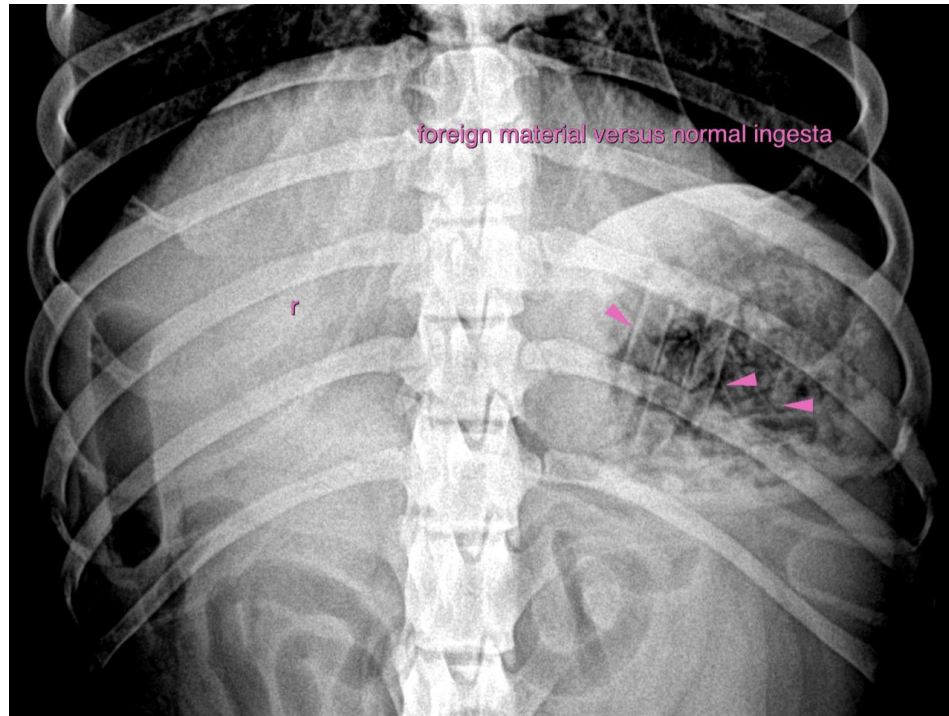
Dr. Medhat Meawad

**INVOICE**

52512

**DATE**

6-17-22



The information and recommendations provided are based on the images presented by the referring veterinarian/sonographer. No evaluation can be communicated regarding pathology that was not visible in the image/video clips provided.

Thank you for this referral. If the clinical or image interpretation does not parallel your findings or if I can be of any further assistance please contact me.

**Sebastian Schaub**, Sebastian Schaub, DVM, Dr. med. vet. DipECVDI  
sebast.schaub@gmail.com