



PATIENT

Hagrid Schroeder

SPECIES

Canine

BREED

Bernese Mountain
Dog

SEX

MN

AGE

7.5 Years

INTERPRETED BY

Sebastian Schaub, DVM
Dr. med. vet. DipECVDI

HOSPITAL NAME

Bridgwater
Veterinary Hospital
and Wellness Centre

REFERRING VET

Dr. Candace Wenzel

INVOICE

52495

DATE

6-17-22

PRESENTING CLINICAL SIGNS

Generally healthy until Nov 2021. Sore on hind legs and slight effusion L. stifle. Based on lameness evaluation-OA of hips and probable partial tear to Left CCL. Multiple lipomas as well-FNA shows no malignancy. May 13,2022 Lipoma near L3 seems to be growing within the epaxial muscles. Owner is concerned it could be causing nerve compression as he now has a hypermetric gait occasionally.

COMPUTED TOMOGRAPHY OF THE LUMBAR SPINE/PELVIS

A high resolution plain CT study of the lumbar spine & pelvis is provided for review.

COMPUTED TOMOGRAPHIC FINDINGS

The intervertebral discs T13/L1 to L6/L7 are mild to moderately protruding into the vertebral canal, occupying approximately up to 15% of the cross-sectional area of the vertebral canal at the same level. The ventral epidural space is compressed respectively.

Multifocal mild spondylosis formation is seen along the lumbar spine.

The osseous and surrounding soft tissue structures of the pelvis are within normal limits.

COMPUTED TOMOGRAPHIC DIAGNOSIS

- Serial intervertebral disc protrusions along the lumbar spine with possible dynamic myelocompression – most accentuated L2/L3
- Normal pelvis and coxofemoral joints

INTERPRETATION OF THE FINDINGS & FURTHER RECOMMENDATIONS

There is no evidence of infiltrative lipoma formation or evidence of lipoma near the lumbar spine.

The multiple intervertebral disc protrusions along the lumbar spine can be a source for pain but are considered less likely to be associated with neurological deficits.



PATIENT

Hagrid Schroeder

SPECIES

Canine

BREED

Bernese Mountain
Dog

SEX

MN

AGE

7.5 Years

INTERPRETED BY

Sebastian Schaub, DVM
Dr. med. vet. DipECVDI

HOSPITAL NAME

Bridgwater
Veterinary Hospital
and Wellness Centre

REFERRING VET

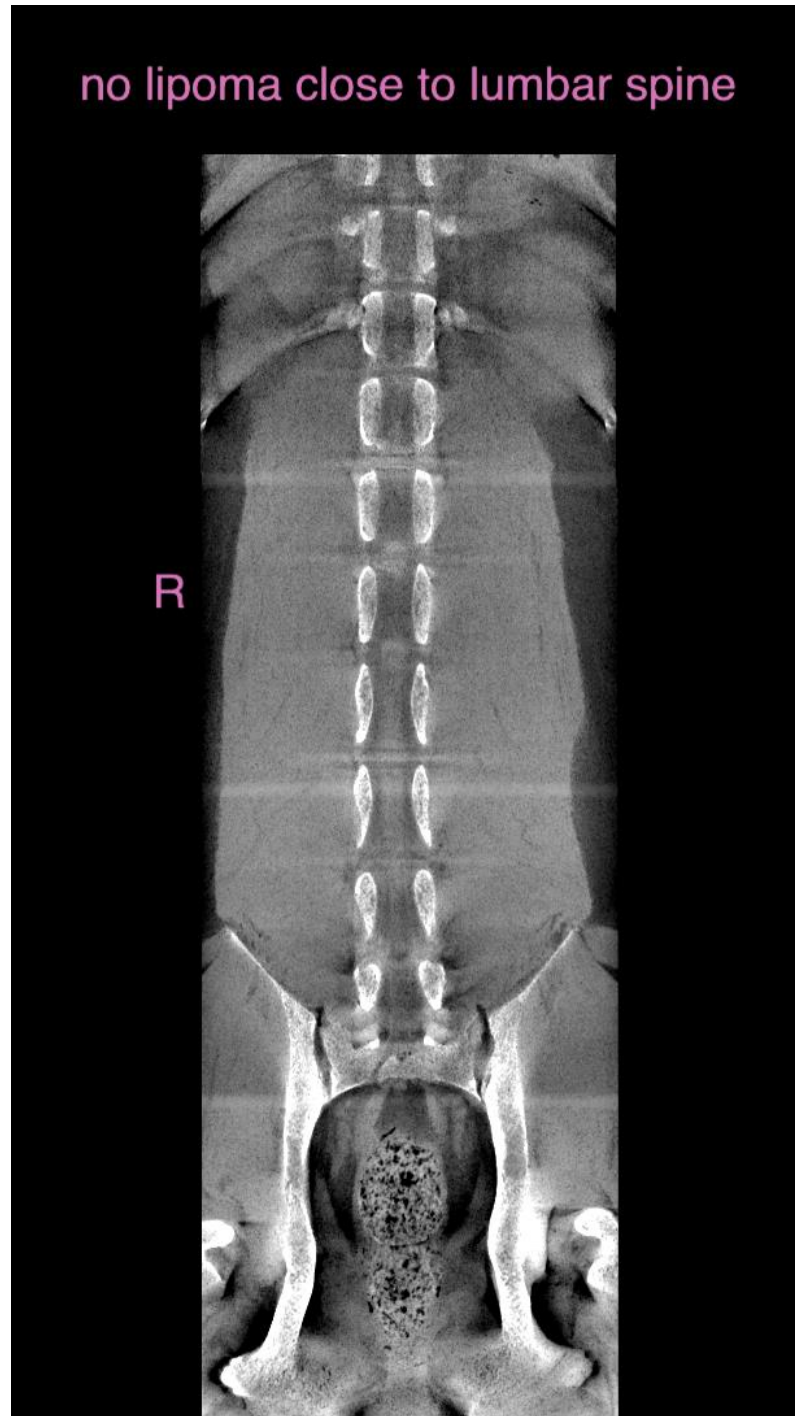
Dr. Candace Wenzel

INVOICE

52495

DATE

6-17-22





PATIENT

Hagrid Schroeder

SPECIES

Canine

BREED

Bernese Mountain
Dog

SEX

MN

AGE

7.5 Years

INTERPRETED BY

Sebastian Schaub, DVM
Dr. med. vet. DipECVDI

HOSPITAL NAME

Bridgwater
Veterinary Hospital
and Wellness Centre

REFERRING VET

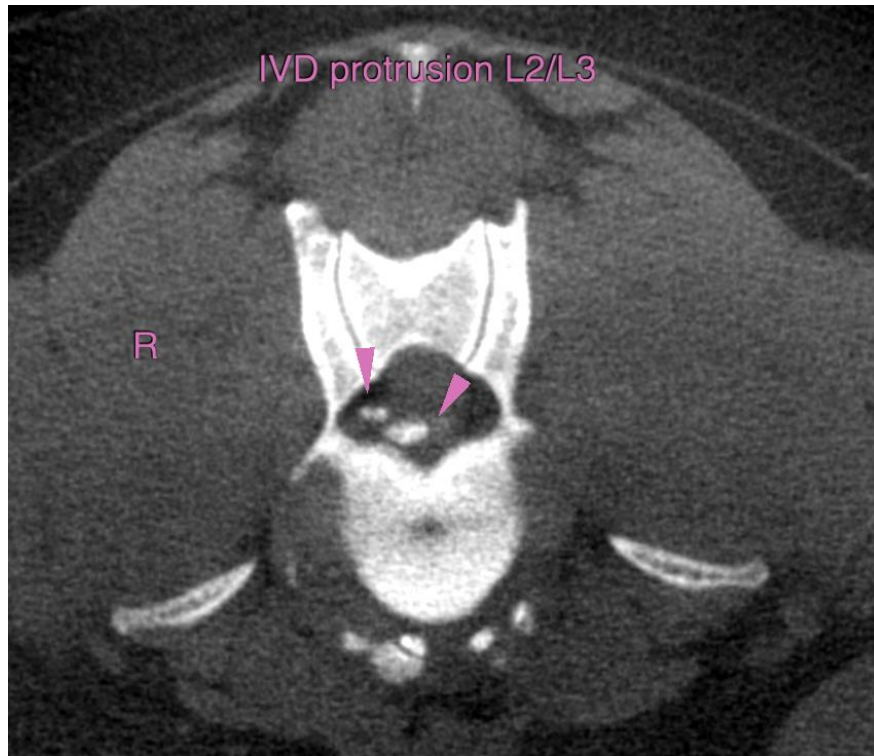
Dr. Candace Wenzel

INVOICE

52495

DATE

6-17-22



The information and recommendations provided are based on the images presented by the referring veterinarian/sonographer. No evaluation can be communicated regarding pathology that was not visible in the image/video clips provided.

Thank you for this referral. If the clinical or image interpretation does not parallel your findings or if I can be of any further assistance please contact me.

Sebastian Schaub, Sebastian Schaub, DVM, Dr. med. vet. DipECVDI
sebast.schaub@gmail.com