



PATIENT

Disco Luck

PRESENTING CLINICAL SIGNS

Vomiting and bloody diarrhea since 06/15/22.
Abnormal PE/Chem/CBC/UA Results: Abdomen tense on palp.

SPECIES

Dog

RADIOGRAPHIC STUDY OF THE ABDOMEN

A Radiographs of the abdomen in two imaging planes are provided for review.

BREED

Goldendoodle

RADIOGRAPHIC FINDINGS

The surrounding bony structures are within normal limits.

No abnormalities of the extraabdominal soft tissues are noted. The abdominal wall is smooth and thin.

The serosal detail is maintained throughout the peritoneal and retroperitoneal space.

SEX

M

The liver is appropriate in position, size and presents uniform opacity.

The splenic head is in the anticipated position and within normal limits for size and opacity. The splenic body and tail are considered normal for position, size, shape and opacity.

AGE

2 Years

Both kidneys are seen and present with normal size, shape, delineation and opacity. The urinary bladder is in its anticipated position. No radiopaque calculi are noted throughout the upper and lower urinary tract.

INTERPRETED BY

Sebastian Schaub, DVM
Dr. med. vet. DipECVDI

The stomach is in its anticipated position and contains a mild amount of gas and fluid.

The small intestinal loops are of even diameter and non-dilated, a small amount of gas is seen within the small intestinal loops and considered within normal limits.

The colon is seen in the expected position and contains a small amount of foamy fecal material.

HOSPITAL NAME

Truscott Animal
Hospital

RADIOGRAPHIC DIAGNOSIS

- Mild fluid and gas filled stomach
- Mild amount of unformed fecal material in colon

REFERRING VET

Dr. Medhat Meawad

INTERPRETATION OF THE FINDINGS & FURTHER RECOMMENDATIONS

The findings of the gastrointestinal tract in combination with the presenting clinical signs are suggestive for underlying gastroenteritis. There is no evidence of radiopaque foreign material or signs for gastrointestinal mechanical obstruction. If clinical signs are refractory to empirical therapy, recommend follow up radiographs or a complete abdominal ultrasound examination; in some cases, a high ileus may lack classical radiographic signs of mechanical obstruction.

INVOICE

52511

DATE

6-17-22



PATIENT

Disco Luck

SPECIES

Dog

BREED

Goldendoodle

SEX

M

AGE

2 Years

INTERPRETED BY

Sebastian Schaub, DVM
Dr. med. vet. DipECVDI

HOSPITAL NAME

Truscott Animal
Hospital

REFERRING VET

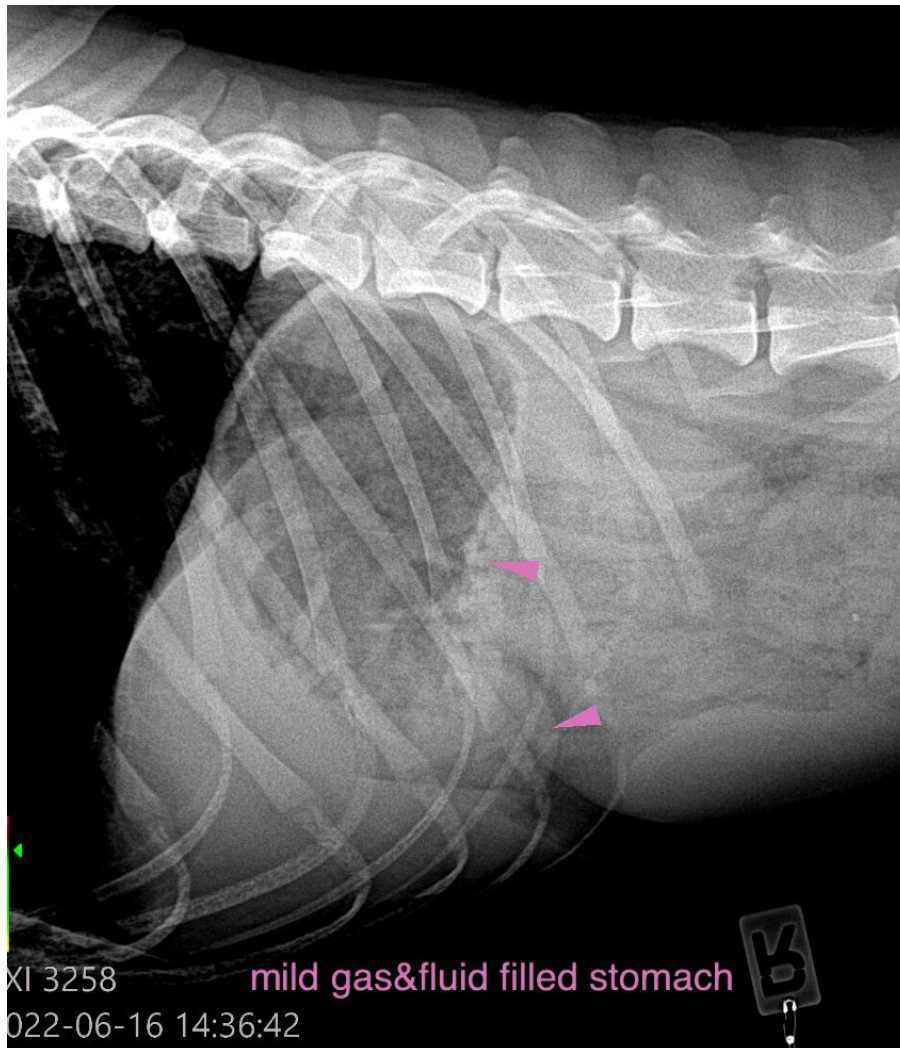
Dr. Medhat Meawad

INVOICE

52511

DATE

6-17-22



The information and recommendations provided are based on the images presented by the referring veterinarian/sonographer. No evaluation can be communicated regarding pathology that was not visible in the image/video clips provided.

Thank you for this referral. If the clinical or image interpretation does not parallel your findings or if I can be of any further assistance please contact me.

Sebastian Schaub, Sebastian Schaub, DVM, Dr. med. vet. DipECVDI
sebast.schaub@gmail.com