



PATIENT PRESENTING CLINICAL SIGNS

Cooper Boucher History: Cooper presented for an ongoing 3-4 month history of having nasal congestion. Patient had some ulcerated sore below the right nares and was prescribed Tacrolimus ointment for topical. Owner stated initially helped but then ulcerated area started to grow in size. Cooper is eating and drinking normally and not on any other medications.

SPECIES

Canine **COMPUTED TOMOGRAPHIC STUDY OF THE SKULL**

A high resolution pre- and post-contrast CT study of the skull is provided for review.

BREED

Golden Retriever

COMPUTED TOMOGRAPHIC FINDINGS

The pictured parts of the dentition are complete and unremarkable in all jaw quadrants.

SEX

Male

The mucosal lining of the nares is irregularly thickened bilaterally, L>R. The nasal cavity presents the expected aerated spaces between thin & even conchae and turbinates with smooth mucosal lining.

AGE

8 Years

Both temporomandibular joints present congruent joint spaces with even subchondral bone surfaces and are considered within normal limits.

Both tympanic bullae are aerated, the mucosal lining is not seen, the bony wall is smooth and thin. The external ear canals are within normal limits.

INTERPRETED BY

Sebastian Schaub,
DVM Dr. med. vet.
DipECVDI

The brain presents no deviation from normal anatomy and symmetry. The brain parenchyma is homogeneous and within normal limits for attenuation and distribution of contrast enhancement. The ventricular system is non-dilated and symmetric.

The right mandibular lymph nodes are prominent in comparison to the contralateral side.

HOSPITAL NAME

Critical Vet
Care/Suncoast Vet

COMPUTED TOMOGRAPHIC DIAGNOSIS

- Mucosal thickening nasal opening bilaterally, L>R
- Mild lymphadenopathy right mandibular lymph nodes

INTERPRETATION OF THE FINDINGS & FURTHER RECOMMENDATIONS

REFERRING VET

Dr. Young

The thickening of the mucosal lining of the nares is fitting the history but is not specific – it can be inflammatory in origin (e.g. immune mediated disease) or present neoplastic transformation (e.g. squamous cell carcinoma, melanoma). If not done so yet, recommend biopsy for further workup. FNA sampling of the enlarged right mandibular lymph nodes is beneficial as well.

INVOICE

16177

DATE

6/17/22



PATIENT

Cooper Boucher

SPECIES

Canine

BREED

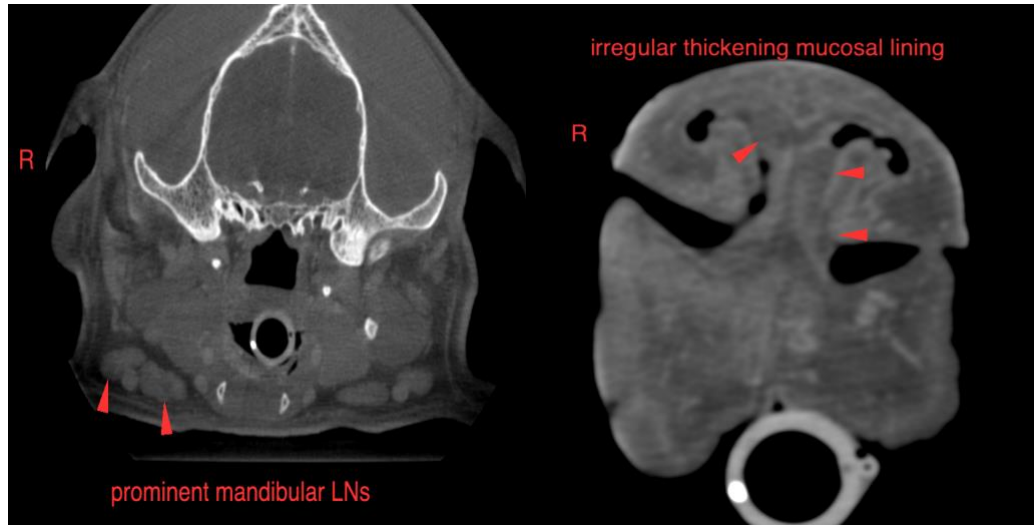
Golden Retriever

SEX

Male

AGE

8 Years



The information and recommendations provided are based on the images presented by the referring veterinarian/sonographer. No evaluation can be communicated regarding pathology that was not visible in the image/video clips provided.

Thank you for this referral. If the clinical or image interpretation does not parallel your findings or if I can be of any further assistance please contact me.

INTERPRETED BY

Sebastian Schaub, Sebastian Schaub, DVM, Dr. med. vet. DipECVDI
sebast.schaub@gmail.com

Sebastian Schaub,
DVM Dr. med. vet.
DipECVDI

HOSPITAL NAME

Critical Vet
Care/Suncoast Vet

REFERRING VET

Dr. Young

INVOICE

16177

DATE

6/17/22