

**PATIENT PRESENTING CLINICAL SIGNS**

Bun Bun Galamaga History: Left otitis media.

**COMPUTED TOMOGRAPHIC STUDY OF THE SKULL****SPECIES**

Lagamorph

A high resolution pre- and post-contrast CT study of the skull is provided for review.

**COMPUTED TOMOGRAPHIC FINDINGS****BREED**

Rabbit

The pictured parts of the dentition are complete and unremarkable in all jaw quadrants, but mild step formation between 301 & 401.

The nasal cavity presents the expected aerated spaces between thin & even conchae and turbinates with smooth mucosal lining.

**SEX**

Unknown

Both temporomandibular joints present congruent joint spaces with even subchondral bone surfaces and are considered within normal limits.

**AGE**

4-5 Years

The left tympanic bulla is filled with non-contrast enhancing soft tissue material. The osseous lining of the left tympanic bulla is mildly thickened and smooth. The left porous acoustic externus is widened. The left external ear canal is moderately widened and occupied by soft tissue material.

The lumen of the right external ear canal is significantly narrowed.

**INTERPRETED BY**

Sebastian Schaub, DVM  
Dr. med. vet. DipECVDI

**COMPUTED TOMOGRAPHIC DIAGNOSIS**

- Bilateral otitis externa
- Left sided otitis media
- No evidence of otitis interna
- Normal dentition

**HOSPITAL NAME**

Mobile Pet Imaging

**INTERPRETATION OF THE FINDINGS & FURTHER RECOMMENDATIONS****REFERRING VET**

Dr. Meaux

As the patient appears to be a lop-eared rabbit, the otitis media can be a sequela to primary otitis externa/ear based swelling' where cerumen cannot drain from soft part of the external ear canal. Surgical management with left sided total ear canal ablation might be considered.

\*\*[http://vetpracticetoday.com/vpt-en/catalogs/vpt7-1\\_rabbits/pdf/complete.pdf](http://vetpracticetoday.com/vpt-en/catalogs/vpt7-1_rabbits/pdf/complete.pdf)

**INVOICE**

16183

**DATE**

6/17/22



**PATIENT**

Bun Bun Galamaga

**SPECIES**

Lagamorph

**BREED**

Rabbit

**SEX**

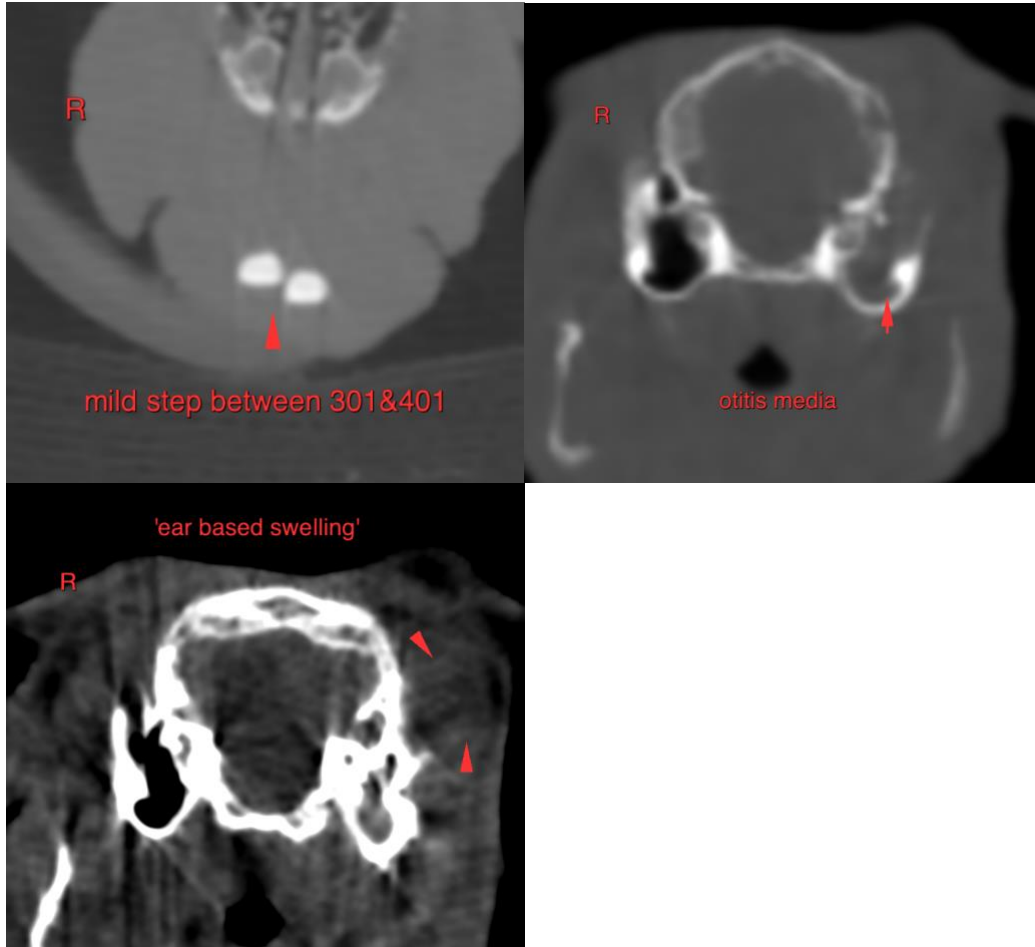
Unknown

**AGE**

4-5 Years

**INTERPRETED BY**

Sebastian Schaub, DVM  
Dr. med. vet. DipECVDI



**HOSPITAL NAME**

Mobile Pet Imaging

The information and recommendations provided are based on the images presented by the referring veterinarian/sonographer. No evaluation can be communicated regarding pathology that was not visible in the image/video clips provided.

**REFERRING VET**

Dr. Meaux

Thank you for this referral. If the clinical or image interpretation does not parallel your findings or if I can be of any further assistance please contact me.

**Sebastian Schaub**, Sebastian Schaub, DVM, Dr. med. vet. DipECVDI  
sebast.schaub@gmail.com

**INVOICE**

16183

**DATE**

6/17/22



**PATIENT**

Bun Bun Galamaga

**SPECIES**

Lagamorph

**BREED**

Rabbit

**SEX**

Unknown

**AGE**

4-5 Years

**INTERPRETED BY**

Sebastian Schaub, DVM  
Dr. med. vet. DipECVDI

**HOSPITAL NAME**

Mobile Pet Imaging

**REFERRING VET**

Dr. Meaux

**INVOICE**

16183

**DATE**

6/17/22