



PATIENT PRESENTING CLINICAL SIGNS

Brandy Sempey Ultrasound concerning bilateral adrenal masses.

COMPUTED TOMOGRAPHY OF THE ABDOMEN

SPECIES A high resolution pre- and post-contrast CT study of abdomen is provided for review.

Canine **COMPUTED TOMOGRAPHIC FINDINGS**

The serosal fat presents normal attenuation behavior. There is no evidence of peritoneal effusion or peritonitis.

BREED Both kidneys present within normal limits for size, shape and organ architecture. After contrast administration a bilaterally symmetric and uniform nephro- and pyelogram is noted.

Schnauzer The diameter of the left adrenal gland is mildly increased, measuring 7.9 mm. The adrenal glands are within normal limits for shape and organ architecture.

SEX Both liver and spleen present with normal shape, even surface, uniformly attenuating parenchyma and homogeneous contrast enhancement, unremarkable.

Female Spayed

AGE The hepatic volume is moderately increased. The hepatic parenchyma is uniform soft tissue attenuating with a homogeneous contrast enhancement pattern. Multiple well-defined nodular mineralizations of the hepatic parenchyma are appreciated.

13 Years The left hepatic lymph node is prominent and has a mild irregular contrast enhancement pattern. The short-to-long-axis ratio is increased and equals 0.5.

INTERPRETED BY The gallbladder contains a small amount of mineral attenuating, sedimented granular material.

Sebastian Schaub, DVM Dr. med. vet. DipECVDI The pancreas is evenly contoured, the pancreatic parenchyma is homogeneous and presents uniform contrast enhancement.

HOSPITAL NAME The position, delineation, wall and content of the gastrointestinal tract are considered within normal limits throughout.

Mobile Pet Imaging In the subcutaneous tissue at the caudodorsal aspect of the right gluteal region, a well-defined soft tissue attenuating nodule is visible, measuring 5.7 mm in diameter.

REFERRING VET The vertebral endplates of the lumbosacral junction present moderate spondylosis formation.

Meaux **COMPUTED TOMOGRAPHIC DIAGNOSIS**

- Mild prominent left adrenal gland
- Hepatomegaly with randomly distributed nodular mineralization of the hepatic parenchyma
- Lymphadenopathy left hepatic lymph node
- Non-specific subcutaneous nodule right caudodorsal gluteal region
- Cholecystolithiasis without evidence of obstruction

DATE INTERPRETATION OF THE FINDINGS & FURTHER RECOMMENDATIONS

6-17-22 The mild prominent left adrenal gland can still present normal anatomy and the clinical relevance is unclear. Repeating testing of the pituitary adrenal axis appears beneficial.



PATIENT

Brandy Sempey

Potentials for the hepatomegaly include metabolic hepatic disease, hepatitis, or diffuse neoplastic infiltration. In combination with the prominent hepatic lymph node, I consider the odds for chronic hepatitis high. In case of doubt, ultrasound guided FNA sampling and/or Tru-cut biopsy can be used as minimally invasive methods for further workup. The dystrophic mineralization of the hepatic parenchyma are considered as a sequela to chronic hepatic disease or mineralization of the intrahepatic biliary tree.

SPECIES

Canine

BREED

Schnauzer

SEX

Female Spayed

AGE

13 Years

INTERPRETED BY

Sebastian Schaub, DVM
Dr. med. vet. DipECVDI

HOSPITAL NAME

Mobile Pet Imaging

REFERRING VET

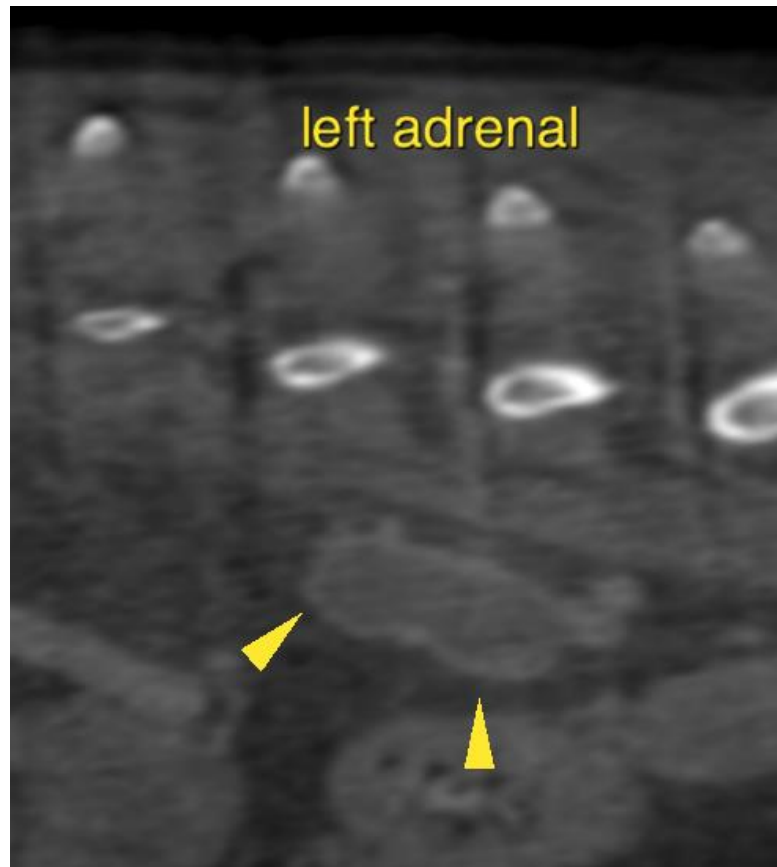
Meaux

INVOICE

52479

DATE

6-17-22





PATIENT

Brandy Sempey

SPECIES

Canine

BREED

Schnauzer

SEX

Female Spayed

AGE

13 Years

INTERPRETED BY

Sebastian Schaub, DVM
Dr. med. vet. DipECVDI

HOSPITAL NAME

Mobile Pet Imaging

REFERRING VET

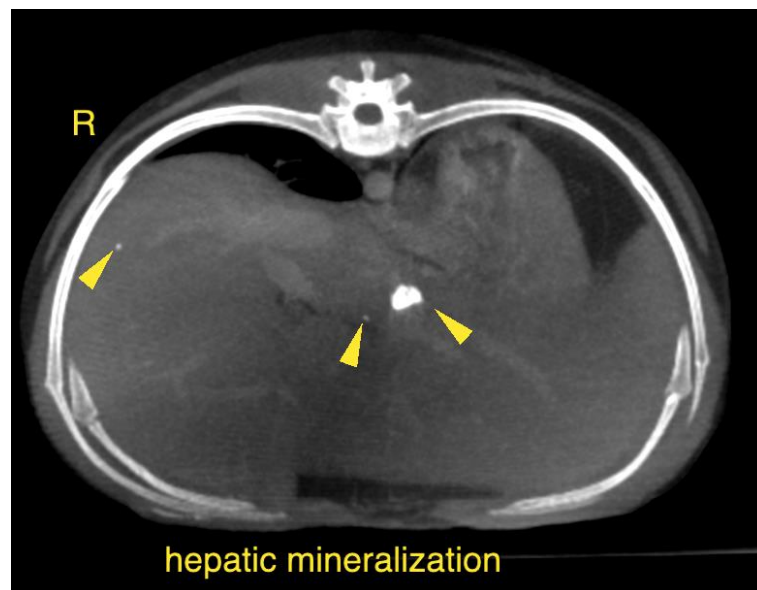
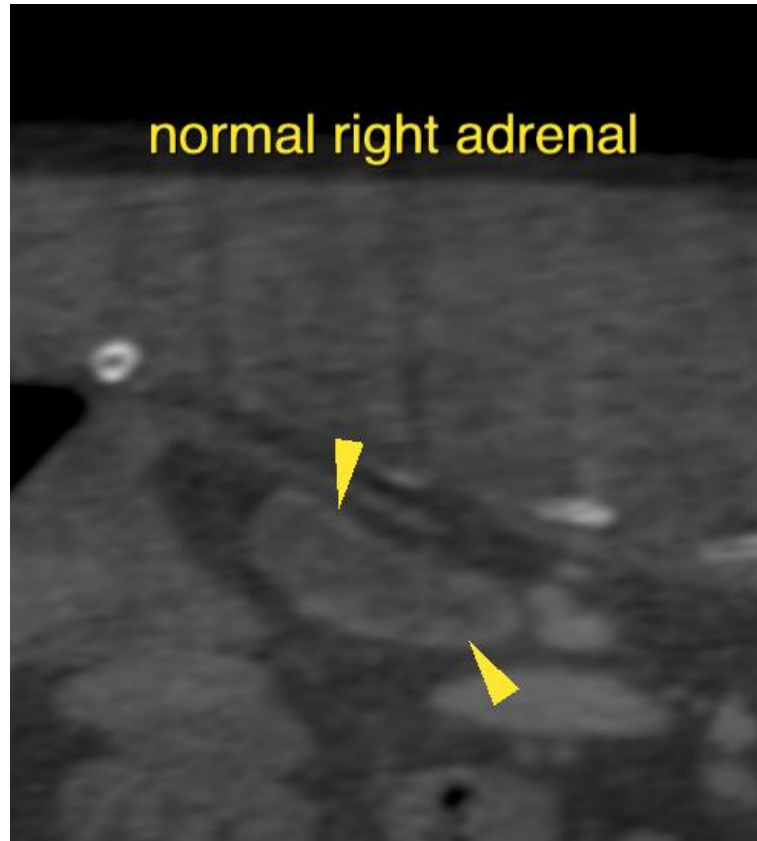
Meaux

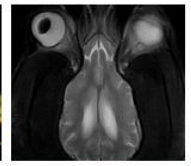
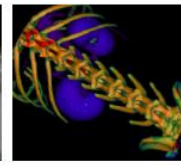
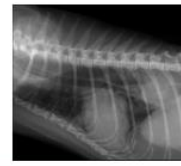
INVOICE

52479

DATE

6-17-22





PATIENT

Brandy Sempey

The information and recommendations provided are based on the images presented by the referring veterinarian/sonographer. No evaluation can be communicated regarding pathology that was not visible in the image/video clips provided.

SPECIES

Canine

Thank you for this referral. If the clinical or image interpretation does not parallel your findings or if I can be of any further assistance please contact me.

Sebastian Schaub, Sebastian Schaub, DVM, Dr. med. vet. DipECVDI
sebast.schaub@gmail.com

BREED

Schnauzer

SEX

Female Spayed

AGE

13 Years

INTERPRETED BY

Sebastian Schaub, DVM
Dr. med. vet. DipECVDI

HOSPITAL NAME

Mobile Pet Imaging

REFERRING VET

Meaux

INVOICE

52479

DATE

6-17-22