

**PATIENT PRESENTING CLINICAL SIGNS**

Archer Carrero Unilateral cryptorchid, previous Sx, and ultrasound. Unable to locate other testicle.  
Abnormal PE/Chem/CBC/UA Results: Anti-Mullerian hormone: positive

**SPECIES COMPUTED TOMOGRAPHY OF THE ABDOMEN**

Feline A high resolution pre- and post-contrast CT study of the abdomen is provided for review.

**COMPUTED TOMOGRAPHIC FINDINGS**

The serosal fat presents normal attenuation behavior. There is no evidence of peritoneal effusion or peritonitis.

**BREED**

American Short Hair Both kidneys present within normal limits for size, shape and organ architecture. After contrast administration a bilaterally symmetric and uniform nephro- and pyelogram is noted.

**SEX**

The adrenal glands are within normal limits for size, shape and organ architecture.

Intact Male

Both liver and spleen present with normal shape, even surface, uniformly attenuating parenchyma and homogeneous contrast enhancement, unremarkable.

**AGE**

The portal vein presents a normal order of its tributary veins and intrahepatic branching. No abnormal vessel is noted inside and outside of the liver parenchyma.

9 Months

The pancreas is evenly contoured, the pancreatic parenchyma is homogeneous and presents uniform contrast enhancement.

**INTERPRETED BY**

The position, delineation, wall and content of the gastrointestinal tract are considered within normal limits throughout.

Sebastian Schaub, DVM  
Dr. med. vet. DipECVDI

Both testicles are appreciated at the same level in the subcutaneous tissue in the midline, ventral to the pelvis.

**HOSPITAL NAME****COMPUTED TOMOGRAPHIC DIAGNOSIS**

Mobile Pet Imaging

- Bilateral inguinal cryptorchism

**REFERRING VET****INTERPRETATION OF THE FINDINGS & FURTHER RECOMMENDATIONS**

Meaux

Both testicles are appreciated in the subcutaneous tissue ventral to the pelvis.

**INVOICE**

52493

**DATE**

6-17-22



**PATIENT**

Archer Carrero

**SPECIES**

Feline

**BREED**

American Short Hair

**SEX**

Intact Male

**AGE**

9 Months

**INTERPRETED BY**

Sebastian Schaub, DVM  
Dr. med. vet. DipECVDI

**HOSPITAL NAME**

Mobile Pet Imaging

**REFERRING VET**

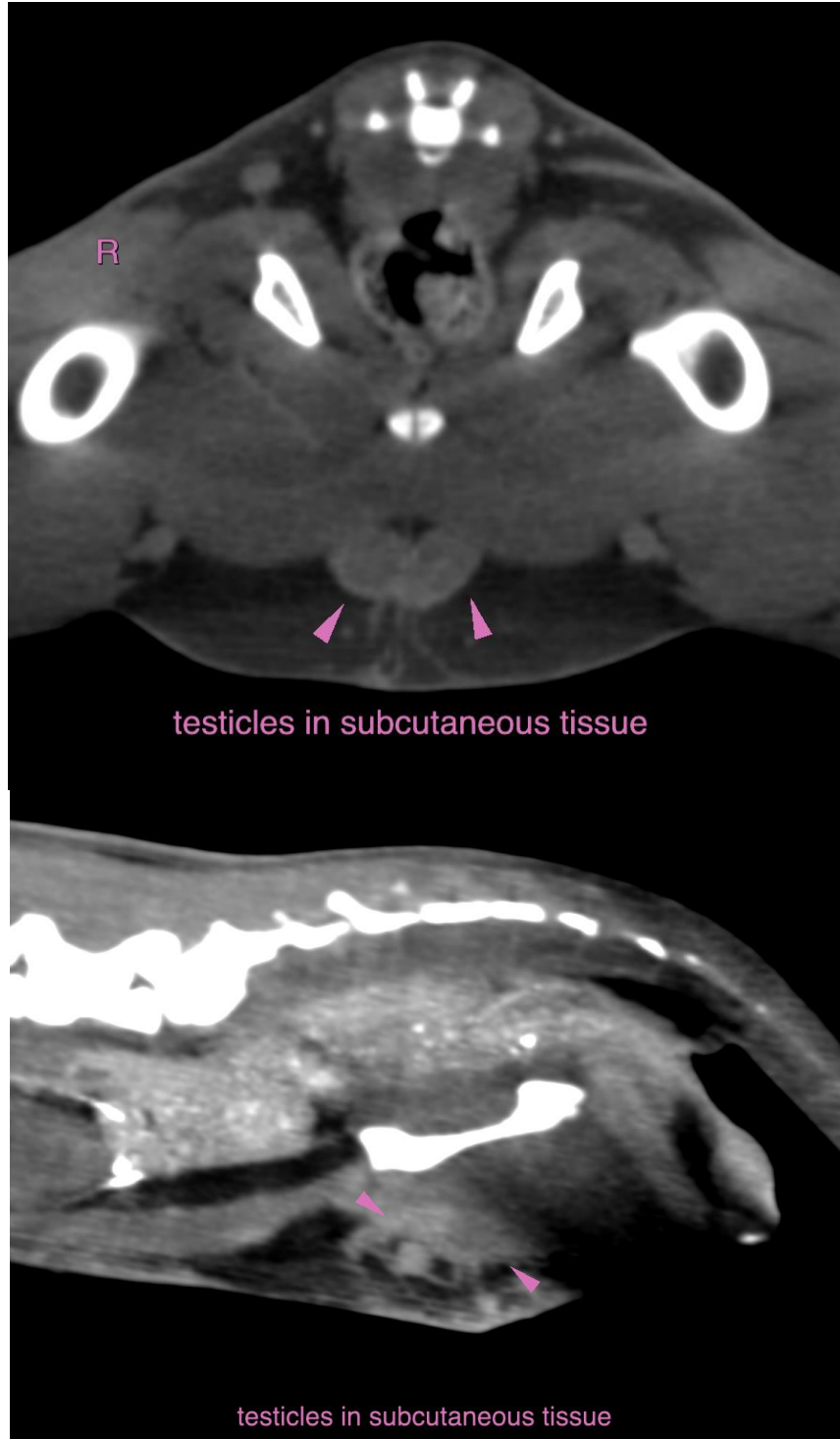
Meaux

**INVOICE**

52493

**DATE**

6-17-22



**PATIENT**

Archer Carrero

**SPECIES**

Feline

The information and recommendations provided are based on the images presented by the referring veterinarian/sonographer. No evaluation can be communicated regarding pathology that was not visible in the image/video clips provided.

Thank you for this referral. If the clinical or image interpretation does not parallel your findings or if I can be of any further assistance please contact me.

**BREED**

American Short Hair

**Sebastian Schaub**, Sebastian Schaub, DVM, Dr. med. vet. DipECVDI  
sebast.schaub@gmail.com

**SEX**

Intact Male

**AGE**

9 Months

**INTERPRETED BY**

Sebastian Schaub, DVM  
Dr. med. vet. DipECVDI

**HOSPITAL NAME**

Mobile Pet Imaging

**REFERRING VET**

Meaux

**INVOICE**

52493

**DATE**

6-17-22