



PATIENT PRESENTING CLINICAL SIGNS

Gigi Marcos see attached internal medicine report

COMPUTED TOMOGRAPHY OF THE SKULL, THORAX AND ABDOMEN

SPECIES A high resolution pre- and post-contrast CT study of the skull and a post-contrast CT study of the thorax and abdomen are provided for review.

Canine

COMPUTED TOMOGRAPHIC FINDINGS

BREED Skull

Rottweiler

Triadan 103 presents a mild to moderate periapical widening of the periodontal space.

The nasal cavity presents the expected aerated spaces between thin & even conchae and turbinates with smooth mucosal lining.

SEX

Spayed Female

Both temporomandibular joints present congruent joint spaces with even subchondral bone surfaces and are considered within normal limits.

AGE

9 Years, 7 Months

Both tympanic bullae are aerated, the mucosal lining is not seen, the bony wall is smooth and thin. The external ear canals are mildly narrowed, and the wall presents mild to moderate shell like mineralization.

The brain presents no deviation from normal anatomy and symmetry. The brain parenchyma is homogeneous and within normal limits for attenuation and distribution of contrast enhancement. The ventricular system is non-dilated and symmetric.

INTERPRETED BY

Sebastian Schaub, DVM
Dr. med. vet. DipECVDI

The submandibular and medial retropharyngeal lymph nodes are small and elongated with a normal short-to-long-axis-ratio is < 0.5, the attenuation and contrast enhancement pattern is uniform.

Thorax

HOSPITAL NAME

Mobile Pet Imaging

Multifocal mild spondylosis formation is seen along the thoracic spine.

The sternal, cranial mediastinal and tracheobronchial lymph nodes are small elongated with a normal short-to-long-axis-ratio is < 0.5, the attenuation and contrast enhancement pattern is uniform and considered within normal limits.

REFERRING VET

Meaux

The cardiovascular structures including the pulmonary vasculature are within normal limits.

The bronchial tree presents with regular branching and tapers uniformly towards the periphery as expected, the bronchial walls are thin and smooth. The bronchus-to-artery ratio is within normal limits.

INVOICE

52474

Multifocal punctuate mineralization of the lung parenchyma is appreciated. Level with the 5th intercostal space, in the laterodorsal aspect of the right middle lung lobe, a solitary, well-defined, soft tissue attenuating nodular lesions measuring 6.3 mm in size is appreciated. A roundish region of ground-glass opacification is seen in the accessory lung lobe, just medial to the caudal vena cava.

DATE

6-15-22

Small incidental gas pockets are seen within the esophageal lumen, there is no evidence of abnormal dilation.

Abdomen



PATIENT The serosal fat presents normal attenuation behavior. There is no evidence of peritoneal effusion or peritonitis.

Gigi Marcos Both kidneys present within normal limits for size, shape and organ architecture. After contrast administration a bilaterally symmetric and uniform nephro- and pyelogram is noted.

SPECIES The adrenal glands are within normal limits for size, shape and organ architecture.

Canine Both liver and spleen present with normal shape, even surface, uniformly attenuating parenchyma and homogeneous contrast enhancement, unremarkable.

BREED The pancreas is evenly contoured, the pancreatic parenchyma is homogeneous and presents uniform contrast enhancement.

Rottweiler A small amount of hyperattenuating material is seen in the pyloric antrum.

SEX Multifocal spondylosis formation is seen along the lumbar spine. Both coxofemoral joints present moderate to marked osteophyte new bone formation, R>L. The acetabular groove bilaterally is shallow, and the center of the femoral heads is lateral to the dorsal acetabular rim.

Spayed Female

COMPUTED TOMOGRAPHIC DIAGNOSIS

- Two nodular lung lesions
- Periapical granuloma 103
- Dystrophic mineralization external ear canals
- Pulmonary osteomas
- Degenerative osteoarthritis coxofemoral joints bilaterally, due to hip dysplasia, R>L
- Spondylosis deformans
- Normal nasal cavity

INTERPRETED BY

Sebastian Schaub, DVM
Dr. med. vet. DipECVDI

INTERPRETATION OF THE FINDINGS & FURTHER RECOMMENDATIONS

HOSPITAL NAME

Mobile Pet Imaging

The nodular lung lesions in combination with the history are concerning for pulmonary metastatic disease. However, due to the low number of lesions, differentials include granuloma, bronchogenic cyst, focal mucus impaction/round pneumonia, fibrosis.

REFERRING VET

Meaux

There is no evidence for neoplastic disease of the nasal cavity or foreign body related rhinitis. Possible causes for epistaxis include immune mediated disease, non-specific rhinitis (e.g. lymphocytic plasmocytic), hyperviscosity syndrome (e.g. Leishmaniosis), other causes for coagulopathy or systemic hypertension.

The hyperattenuating material in the pyloric region of the stomach may indicate functional gastric emptying disorder, there is no evidence of mechanical obstruction.

INVOICE

52474

DATE

6-15-22



PATIENT

Gigi Marcos

SPECIES

Canine

BREED

Rottweiler

SEX

Spayed Female

AGE

9 Years, 7 Months

INTERPRETED BY

Sebastian Schaub, DVM
Dr. med. vet. DipECVDI

HOSPITAL NAME

Mobile Pet Imaging

REFERRING VET

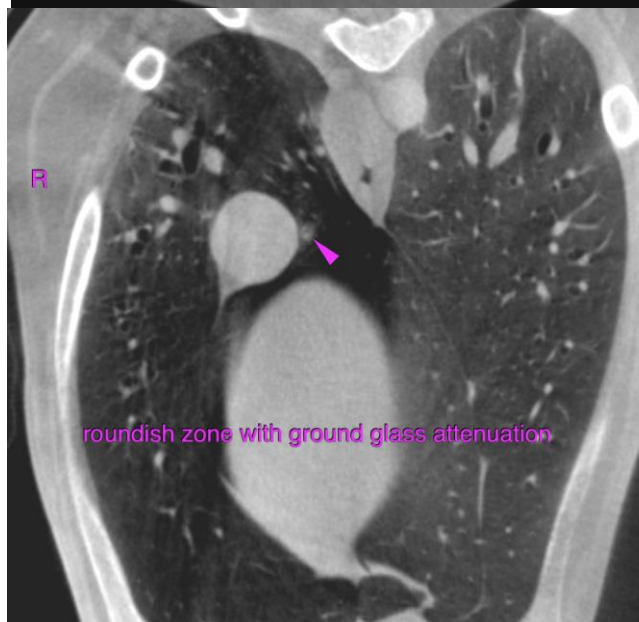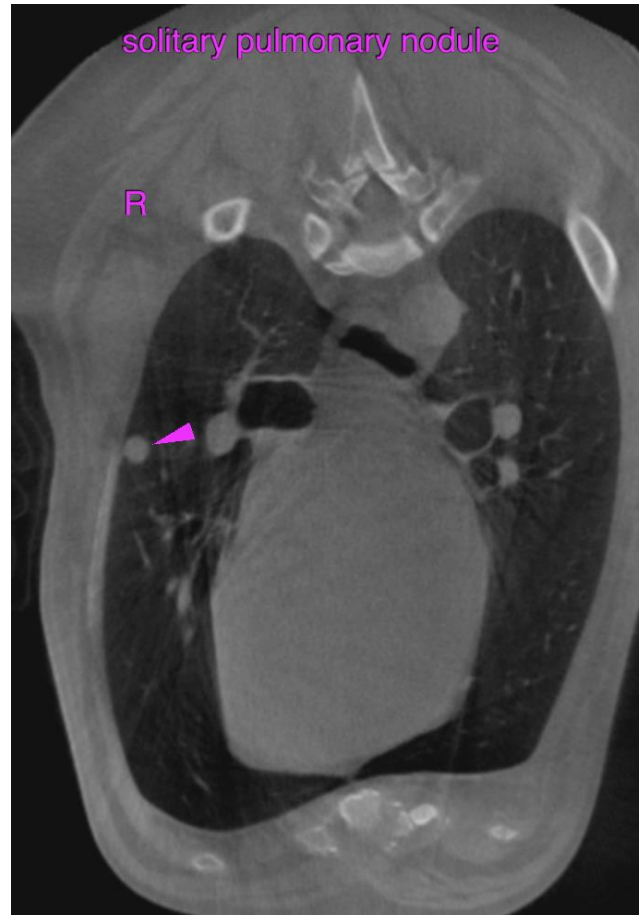
Meaux

INVOICE

52474

DATE

6-15-22





PATIENT

Gigi Marcos

SPECIES

Canine

BREED

Rottweiler

SEX

Spayed Female

AGE

9 Years, 7 Months

INTERPRETED BY

Sebastian Schaub, DVM
Dr. med. vet. DipECVDI

HOSPITAL NAME

Mobile Pet Imaging

REFERRING VET

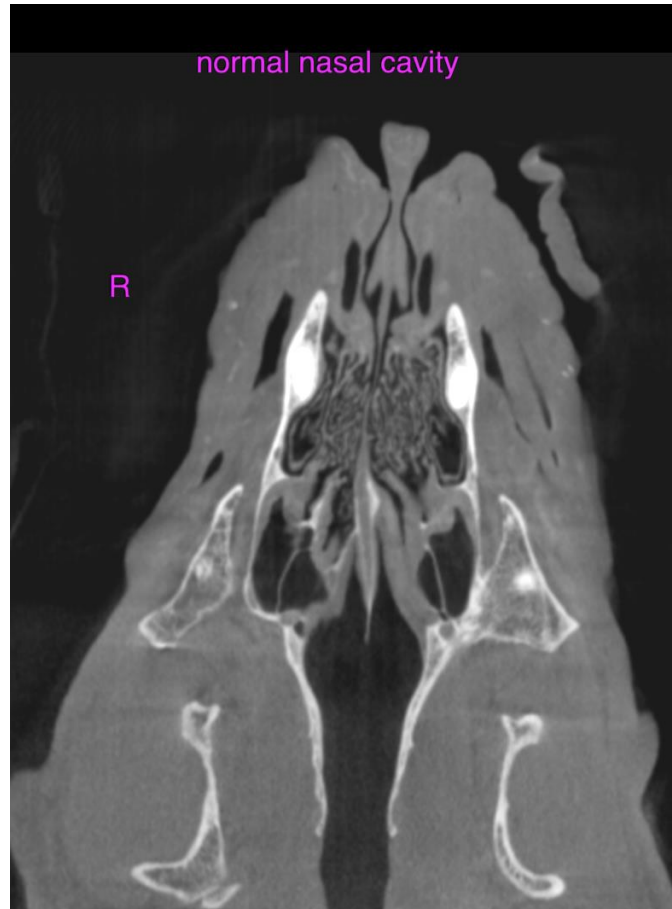Meaux

INVOICE

52474

DATE

6-15-22



The information and recommendations provided are based on the images presented by the referring veterinarian/sonographer. No evaluation can be communicated regarding pathology that was not visible in the image/video clips provided.

Thank you for this referral. If the clinical or image interpretation does not parallel your findings or if I can be of any further assistance please contact me.

Sebastian Schaub, Sebastian Schaub, DVM, Dr. med. vet. DipECVDI
sebast.schaub@gmail.com