



**PATIENT PRESENTING CLINICAL SIGNS**

Elvis Hart History: Large right sided facial mass appeared over one weeks time. Very painful to the touch and draining purulent discharge over the face and from the nostril.  
Abnormal PE/Chem/CBC/UA Results:

**SPECIES COMPUTED TOMOGRAPHIC STUDY OF THE SKULL & THORAX**

Canine A high resolution plain CT study of the skull and thorax are provided for review.

**BREED COMPUTED TOMOGRAPHIC FINDINGS**

Samoyed **Skull**

**SEX** Moderate motion artefacts are present level with the neurocranium/cranial neck.

Neutered Male The pictured parts of the dentition are complete and unremarkable in all jaw quadrants.

**AGE** The right nasal cavity is occupied by soft tissue attenuating material. Advanced destruction of the associated nasal conchal&turbinates structures is appreciated. The right maxillary bone presents with moth eaten osteolytic lesions. The right nasal soft tissue material is perforating the nasal septum and is mildly bulging into the left nasal cavity. Mild immature periosteal new bone formation is appreciated at the lateral aspect of the right maxillary bone. A moderate subcutaneous swelling is seen at the lateral aspect of the left maxillary bone.

12 Years

**INTERPRETED BY** Both temporomandibular joints present congruent joint spaces with even subchondral bone surfaces and are considered within normal limits.

Sebastian Schaub,  
DVM Dr. med. vet.  
DipECVDI

Both tympanic bullae are aerated, the mucosal lining is not seen, the bony wall is smooth and thin. The external ear canals are within normal limits.

**HOSPITAL NAME**

Aloha Pet & Bird

The submandibular and medial retropharyngeal lymph nodes are small and elongated with a normal short-to-long-axis-ratio is < 0.5, the attenuation pattern is uniform.

**Thorax**

**REFERRING VET**

Dr. Hill

Multifocal moderate spondylosis formation is seen along the thoracic spine. In the subcutaneous tissue at the left cranioventral abdominal wall, a well-defined roundish, uniform fat attenuating nodule measuring 3.5 cm in size is appreciated. The periarticular bones of both shoulder joints present moderate osteophyte new bone formation. At the caudodistal aspect of the left humeral head, two well circumscribed roundish mineralized bodies are seen, measuring up to 1.3 cm in size.

**INVOICE**

16114

The sternal, cranial mediastinal and tracheobronchial lymph nodes are small elongated with a normal short-to-long-axis-ratio is < 0.5.

**DATE**

6/15/22



**PATIENT** The cardiovascular structures including the pulmonary vasculature are within normal limits.

Elvis Hart The bronchial tree presents with regular branching and tapers uniformly towards the periphery as expected, the bronchial walls are thin and smooth. The bronchus-to-artery ratio is within normal limits.

**SPECIES** The right middle and cranial lung lobe present regions with dystelectasis. The lung parenchyma presents the expected architecture and attenuation behavior.

Canine Small incidental gas pockets are seen within the esophageal lumen, there is no evidence of abnormal dilation.

**BREED COMPUTED TOMOGRAPHIC DIAGNOSIS**

- Samoyed
- Soft tissue mass right nasal cavity with polyostotic aggressive predominant osteolytic lesions of the associated osseous structures
  - Dystelectasis of the lung due to general anesthesia
  - Lipoma left cranioventral abdominal wall
- SEX**
- Degenerative osteoarthritis shoulder joints bilaterally and synovial osteochondromatosis left shoulder joint
  - Spondylosis deformans thoracic spine
  - No evidence of pulmonary metastatic disease

Neutered Male

**AGE**

12 Years

**INTERPRETATION OF THE FINDINGS & FURTHER RECOMMENDATIONS**

The CT study is consistent with primary nasal neoplasia, originating from the right nasal cavity. Differentials include adenocarcinoma, squamous cell carcinoma, transitional cell carcinoma, lymphosarcoma, other. FNA sampling/biopsy of the subcutaneous swelling or rhinoscopy including biopsy can be used as advanced diagnostic tests. Based on the results of the advanced diagnostic tests, the chances of radiation therapy can be discussed with oncologist. The Adam tumor stage is T3.

**INTERPRETED BY**

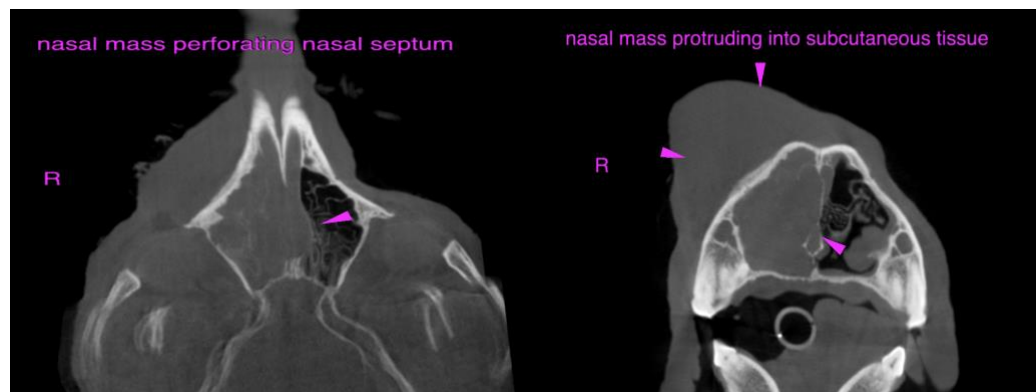
Sebastian Schaub,  
DVM Dr. med. vet.  
DipECVDI

**HOSPITAL NAME**

Aloha Pet & Bird

**REFERRING VET**

Dr. Hill



**INVOICE**

16114

**The information and recommendations provided are based on the images presented by the referring veterinarian/sonographer. No evaluation can be communicated regarding pathology that was not visible in the image/video clips provided.**

**DATE**

6/15/22



**PATIENT** Thank you for this referral. If the clinical or image interpretation does not parallel your findings or if I can be of any further assistance please contact me.

Elvis Hart

**SPECIES**

**Sebastian Schaub**, Sebastian Schaub, DVM, Dr. med. vet. DipECVDI  
sebast.schaub@gmail.com

Canine

**BREED**

Samoyed

**SEX**

Neutered Male

**AGE**

12 Years

**INTERPRETED BY**

Sebastian Schaub,  
DVM Dr. med. vet.  
DipECVDI

**HOSPITAL NAME**

Aloha Pet & Bird

**REFERRING VET**

Dr. Hill

**INVOICE**

16114

**DATE**

6/15/22