



PATIENT

Buddy Vipari

PRESENTING CLINICAL SIGNS

Sore to stand on L leg
Abnormal PE/Chem/CBC/UA Results: Msk: discomfort to put any weight over left hind as well pain reflex during extension and flexion of left stifle

SPECIES

Canine

RADIOGRAPHIC STUDY OF THE STIFLE JOINTS

Radiographs of both stifle joints in two imaging planes are provided for review.

BREED

Jack Russell Terrier
Mix

RADIOGRAPHIC FINDINGS

The right stifle joint presents smooth osseous margins and there is no evidence of intracapsular swelling.

The periarticular bones of the left stifle joint present mild osteophyte new bone formation and a mild to moderate intracapsular soft tissue swelling is appreciated. The left popliteal sesamoid bone is in a relative distal position.

SEX

Male Neuter

RADIOGRAPHIC DIAGNOSIS

- Very mild degenerative osteoarthritis left stifle joint
- Mild articular swelling left stifle joint
- Normal right stifle joint

AGE

4 Years

INTERPRETATION OF THE FINDINGS & FURTHER RECOMMENDATIONS

The radiographic study is consistent with mild degenerative osteoarthritis with concomitant joint effusion of the left stifle joint. The most-likely underlying cause is (partial) rupture of the cranial cruciate ligament with or without meniscal disease.

A positive drawer sign or tibial compression test under general anesthesia can be used to confirm the diagnosis.

INTERPRETED BY

Sebastian Schaub, DVM
Dr. med. vet. DipECVDI

HOSPITAL NAME

St. Catherine's Animal
Hospital

REFERRING VET

Dr. Mena

INVOICE

52470

DATE

6-15-22



PATIENT

Buddy Vipari

SPECIES

Canine

BREED

Jack Russell Terrier
Mix

SEX

Male Neuter

AGE

4 Years

INTERPRETED BY

Sebastian Schaub, DVM
Dr. med. vet. DipECVDI

HOSPITAL NAME

St. Catherine's Animal
Hospital

REFERRING VET

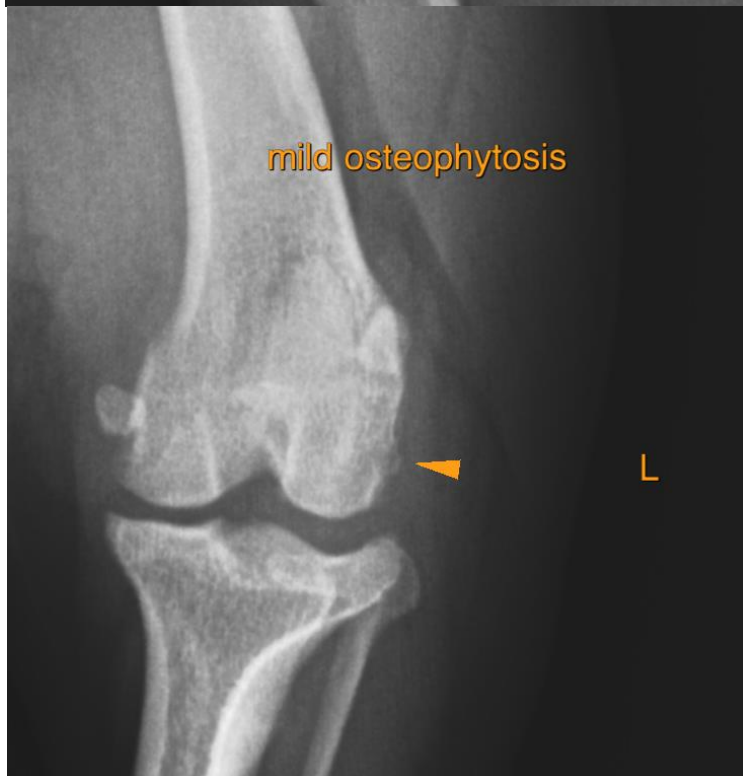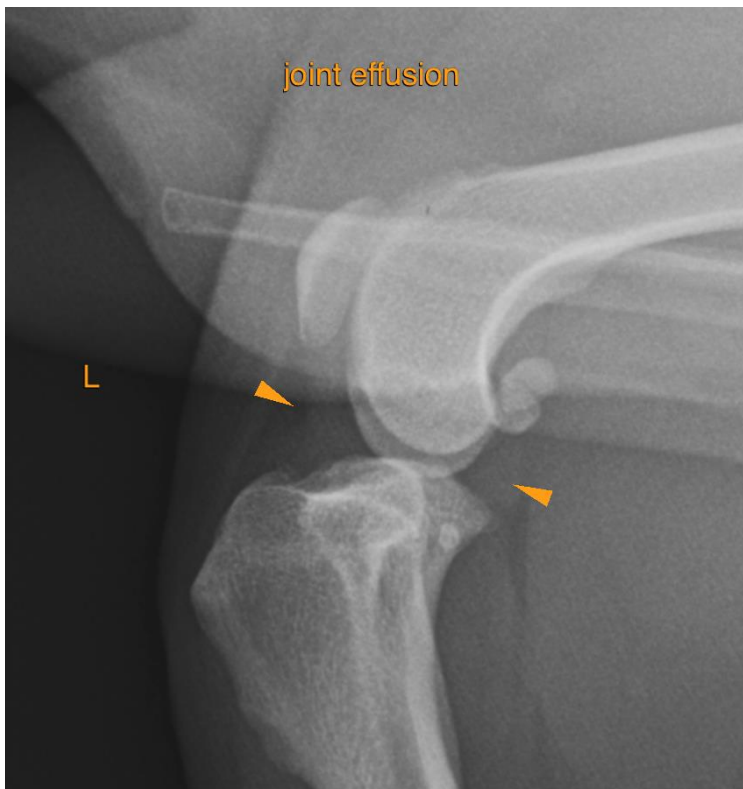
Dr. Mena

INVOICE

52470

DATE

6-15-22





PATIENT

Buddy Vipari

SPECIES

Canine

The information and recommendations provided are based on the images presented by the referring veterinarian/sonographer. No evaluation can be communicated regarding pathology that was not visible in the image/video clips provided.

BREED

Jack Russell Terrier
Mix

Thank you for this referral. If the clinical or image interpretation does not parallel your findings or if I can be of any further assistance please contact me.

Sebastian Schaub, Sebastian Schaub, DVM, Dr. med. vet. DipECVDI
sebast.schaub@gmail.com

SEX

Male Neuter

AGE

4 Years

INTERPRETED BY

Sebastian Schaub, DVM
Dr. med. vet. DipECVDI

HOSPITAL NAME

St. Catherine's Animal
Hospital

REFERRING VET

Dr. Mena

INVOICE

52470

DATE

6-15-22