



PATIENT PRESENTING CLINICAL SIGNS

Ozzy Cohen Family concerned that Ozzy can and will hold his urine for over 0 hours without needing to go outside. No other issues - PE WNL; No C/S/V/D, great appetite without episodes of decreased appetite or inappetence; good activity level with no noted lethargy or exercise intolerance; WNL urine/stool.
SPECIES Abnormal PE/Chem/CBC/UA Results: Superchem/CBC/T4/UA/Accuplex: Pending

Canine **RADIOGRAPHIC STUDY OF THE ABDOMEN**

Radiographs of the abdomen in two imaging planes are provided for review.

BREED RADIOGRAPHIC FINDINGS

Goldendoodle The surrounding bony structures are within normal limits. Along the caudal margin of the ischial bone bilaterally, an isolated ossification center is appreciated.

SEX

No abnormalities of the extraabdominal soft tissues are noted. The abdominal wall is smooth and thin.

Male Neutered

The serosal detail is maintained throughout the peritoneal and retroperitoneal space.

AGE

The liver is appropriate in position, size and presents uniform opacity.
 The splenic head is in the anticipated position and within normal limits for size and opacity. The splenic body and tail are considered normal for position, size, shape and opacity.

10 Months

Only one kidney can be clearly delineated in the lateral projection. The urinary bladder is in its anticipated position. No radiopaque calculi are noted throughout the upper and lower urinary tract.

INTERPRETED BY

The stomach is in its anticipated position and presents normal content.

Sebastian Schaub, DVM
 Dr. med. vet. DipECVDI

The small intestinal loops are of even diameter and non-dilated, a small amount of gas is seen within the small intestinal loops and considered within normal limits.

HOSPITAL NAME

The colon is seen in the expected position and presents with appropriate content.

Summit Dog & Cat
 Hospital

RADIOGRAPHIC DIAGNOSIS

- Normal abdomen
- Incidental isolated ossification center caudal margin ischial bone bilaterally

REFERRING VET

Vogler

INTERPRETATION OF THE FINDINGS & FURTHER RECOMMENDATIONS

The radiographic study of the abdomen presents without abnormalities.

INVOICE

58849

DATE

6-14-23



PATIENT

Ozzy Cohen

SPECIES

Canine

BREED

Goldendoodle

SEX

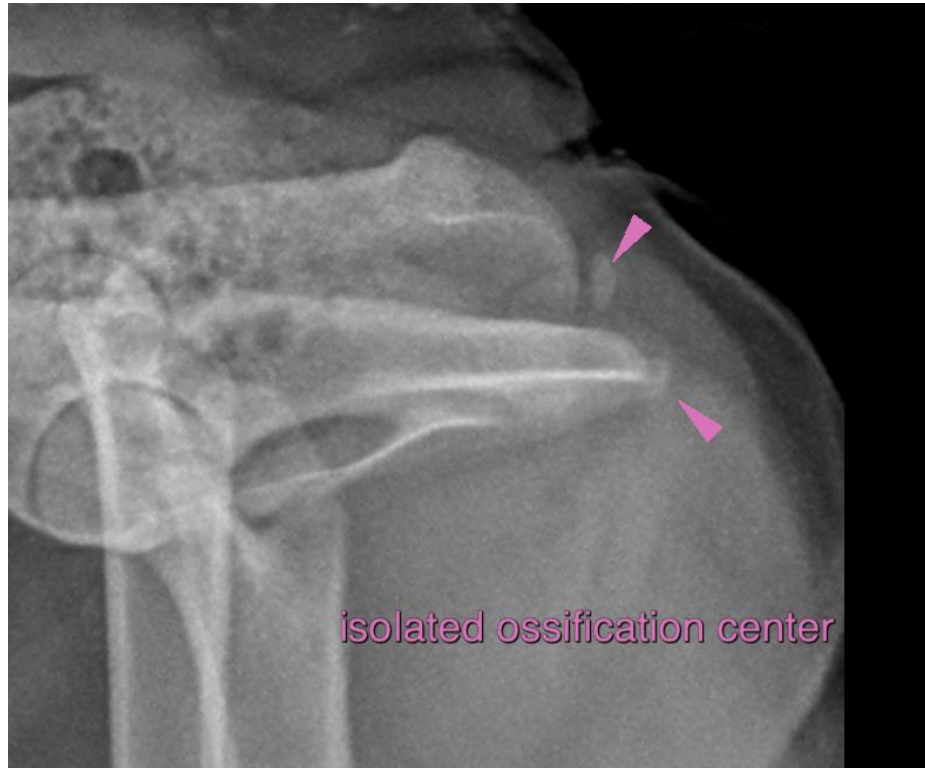
Male Neutered

AGE

10 Months

INTERPRETED BY

Sebastian Schaub, DVM
Dr. med. vet. DipECVDI



HOSPITAL NAME

Summit Dog & Cat
Hospital

The information and recommendations provided are based on the images presented by the referring veterinarian/sonographer. No evaluation can be communicated regarding pathology that was not visible in the image/video clips provided.

REFERRING VET

Vogler

Thank you for this referral. If the clinical or image interpretation does not parallel your findings or if I can be of any further assistance please contact me.

Sebastian Schaub, Sebastian Schaub, DVM, Dr. med. vet. DipECVDI
info@sonopath.com

INVOICE

58849

DATE

6-14-23