



PATIENT PRESENTING CLINICAL SIGNS

Loki Fiore History of left tibial tuberosity avulsion repair at 6 mo of age. Pet has on/off hind limb lameness after rough play and lameness can be right or left sided. Definitive pain not elicited on orthopedic exam. CT of hips and then mid femur to hocks submitted.

SPECIES COMPUTED TOMOGRAPHY OF THE HIND LIMBS

Canine A high resolution plain CT study of the pelvis and hind limbs is provided for review.

COMPUTED TOMOGRAPHIC FINDINGS

BREED The osseous and surrounding soft tissue structures of the pelvis are within normal limits. Both coxofemoral joints present smooth osseous margins and congruent joint spaces.
Pitbull

SEX The periarticular bones of both stifle joints present mild osteophyte new bone formation and a moderate intracapsular soft tissue swelling of the stifle joints is appreciated. The patella is bilaterally in situ. Two surgical pins are seen in the left tibial tuberosity, running in a cranioproximal to caudodistal direction.

MN The osseous and surrounding soft tissue structures of the tarsal joints bilaterally are within normal limits.

AGE COMPUTED TOMOGRAPHIC DIAGNOSIS

3 Years

- Degenerative osteoarthritis stifle joints bilaterally
- Moderate articular swelling both stifle joints
- History of surgical management of cranial tibial tuberosity avulsion
- Normal pelvis & coxofemoral joints
- Normal tarsal joints

INTERPRETED BY

Sebastian Schaub, DVM
Dr. med. vet. DipECVDI

HOSPITAL NAME INTERPRETATION OF THE FINDINGS & FURTHER RECOMMENDATIONS

Pet Emergency &
Referral Center - NVA

The CT study is consistent with bilateral chronic degenerative osteoarthritis with concomitant joint effusion of the stifle joints. The most-likely underlying cause is (partial) rupture of the cranial cruciate ligament ± meniscal disease.

REFERRING VET

A positive drawer sign or tibial compression test under general anesthesia can be used to confirm the diagnosis.

Kara Fiore

INVOICE

58836

DATE

6-14-23



PATIENT

Loki Fiore

SPECIES

Canine

BREED

Pitbull

SEX

MN

AGE

3 Years

INTERPRETED BY

Sebastian Schaub, DVM
Dr. med. vet. DipECVDI

HOSPITAL NAME

Pet Emergency &
Referral Center - NVA

REFERRING VET

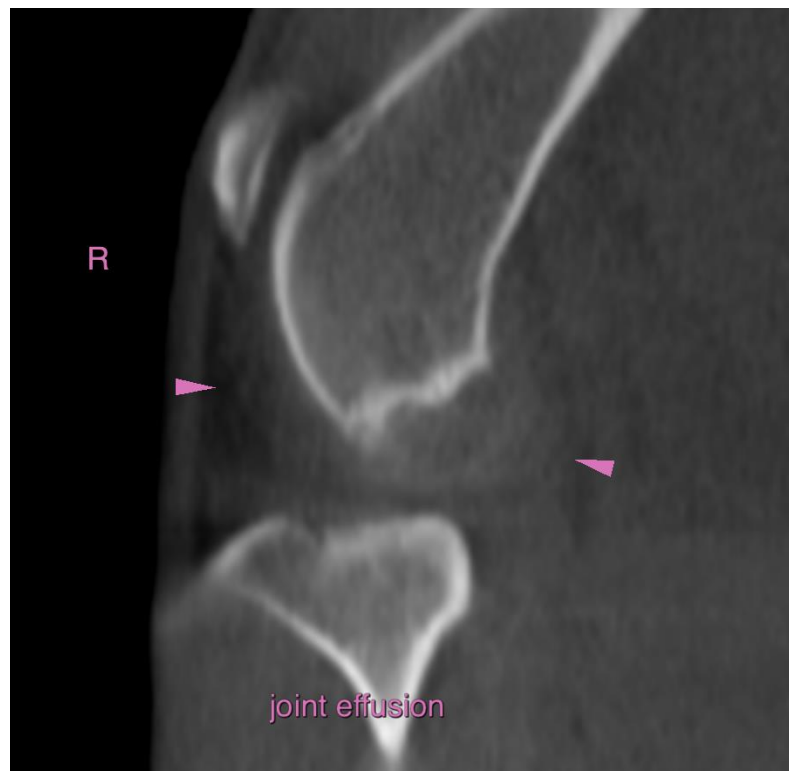
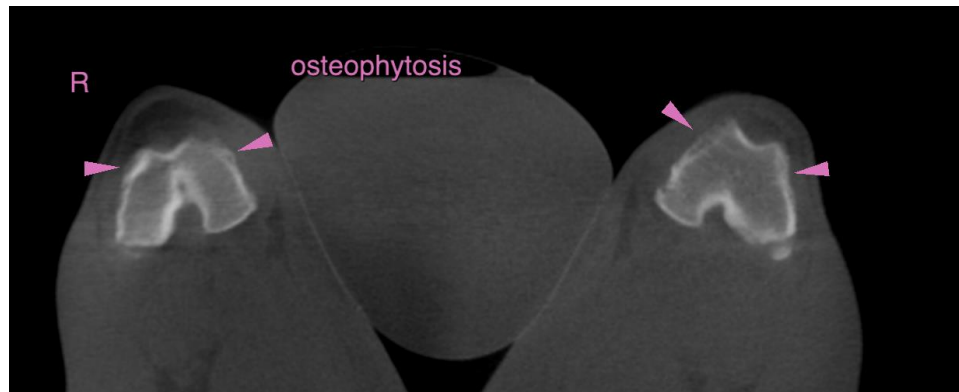Kara Fiore

INVOICE

58836

DATE

6-14-23





PATIENT

Loki Fiore

SPECIES

Canine

BREED

Pitbull

SEX

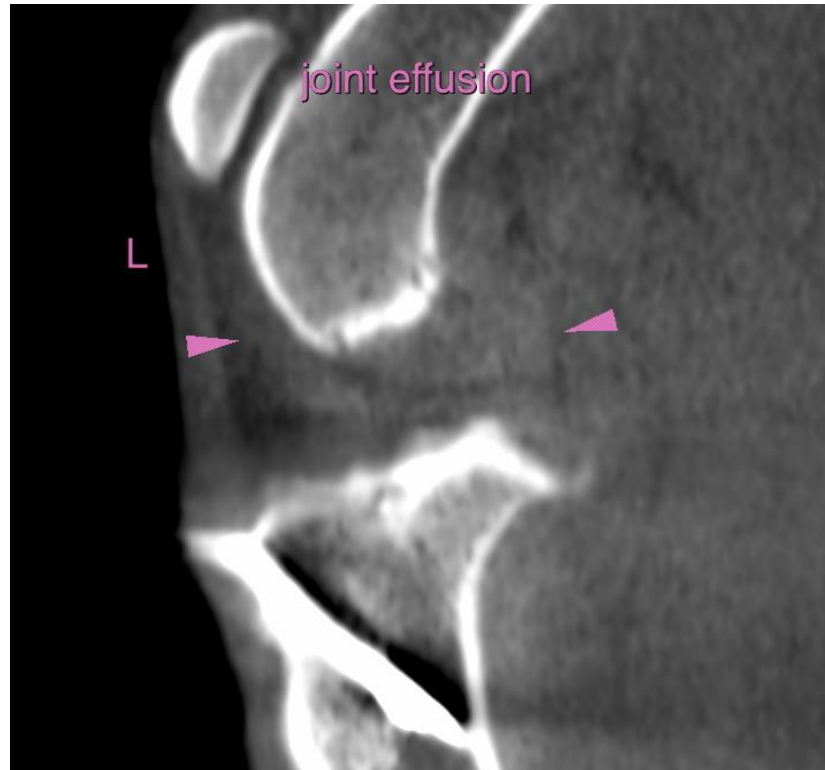
MN

AGE

3 Years

INTERPRETED BY

Sebastian Schaub, DVM
Dr. med. vet. DipECVDI



HOSPITAL NAME

Pet Emergency &
Referral Center - NVA

REFERRING VET

Kara Fiore

INVOICE

58836

DATE

6-14-23

The information and recommendations provided are based on the images presented by the referring veterinarian/sonographer. No evaluation can be communicated regarding pathology that was not visible in the image/video clips provided.

Thank you for this referral. If the clinical or image interpretation does not parallel your findings or if I can be of any further assistance please contact me.

Sebastian Schaub, Sebastian Schaub, DVM, Dr. med. vet. DipECVDI
info@sonopath.com