



PATIENT PRESENTING CLINICAL SIGNS

Bella Abou Cardica patient who is currently on Pimobendan. The patient presented for acute onset vomiting since last night. Two episodes of vomiting were noted as well as decreased appetite. According to the owner, this is a big concern because the patient tends to eat quite a bit. The patient has an unknown history of dietary indiscretions. According to the owner, patient has been diagnosed with pancreatitis in the past
SPECIES Abnormal PE/Chem/CBC/UA Results: CBC: wnl Chemistry: wnl Abdominal ultrasound sent as well for consultation
Canine

RADIOGRAPHIC STUDY OF THE THORAX & ABDOMEN

BREED A complete set of radiographs of the thorax & abdomen is provided for review.

Beagle Mix RADIOGRAPHIC FINDINGS

Thorax

SEX The costal cartilages present degenerative changes.

Female Spayed The extrathoracic soft tissues present homogeneous without abnormalities.

AGE The caudal contour of the cardiac silhouette is steep and the caudal cardiac waist is lost. The lung parenchyma in the perihilar region presents a diffuse ground glass opacity. The pulmonary vasculature is within normal limits.

10 Years The cranial mediastinum presents the expected soft tissue opacity. The mediastinal width is less than twice the width of the vertebral column at the same level.

INTERPRETED BY

The trachea is normal in diameter and presents the anticipated course. The luminal outline of the trachea is smooth.

The bronchial tree presents with thin walls and tapers uniformly towards the periphery as expected.

HOSPITAL NAME

The lung parenchyma presents the expected architecture and opacity; the intrapulmonary vascular branching is seen up to the third order lung vessels.

Paseos Veterinary Center

The diaphragm is well delineated with even surface and the expected mild cranial bulging of the diaphragmatic cupola.

REFERRING VET

Abdomen

Dr. Biello, DVM

The intervertebral disc space L4/L5 is moderately narrowed and the respective vertebral endplates presents moderate spondylosis formation.

No abnormalities of the extraabdominal soft tissues are noted. The abdominal wall is smooth and thin.

INVOICE

The serosal detail is maintained throughout the peritoneal and retroperitoneal space.

58834

The liver is appropriate in position, size and presents uniform opacity.

DATE

The splenic head is in the anticipated position and within normal limits for size and opacity. The splenic body and tail are considered normal for position, size, shape and opacity.

6-14-23

Both kidneys are seen and present with normal size, shape, delineation and opacity. The urinary bladder is in its anticipated position. No radiopaque calculi are noted throughout the upper and lower urinary tract.



PATIENT The stomach is in its anticipated position and presents normal content.

Bella Abou The small intestinal loops are of even diameter and non-dilated, a small amount of ingesta is seen within the small intestinal loops and considered within normal limits.

SPECIES The colon is seen in the expected position and presents with appropriate content.

RADIOGRAPHIC DIAGNOSIS

- Canine
- Unstructured interstitial lung pattern perihilar region of the lung
 - Chronic discopathy L4/L5
- BREED**
- Alimentary pattern gastrointestinal tract

Beagle Mix **INTERPRETATION OF THE FINDINGS & FURTHER RECOMMENDATIONS**

SEX The unstructured interstitial lung pattern in the perihilar region in combination with the history of cardiac disease can indicate cardiogenic pulmonary edema – clinically tachycardia and increased respiration rate are expected.

Female Spayed The abdomen presents without abnormalities, explaining the acute onset of vomiting. The material appreciated throughout the gastrointestinal tract is compatible with ingesta. There is no evidence of radiopaque foreign material, abnormal gas pattern or signs for gastrointestinal mechanical obstruction.

AGE

10 Years

INTERPRETED BY

Sebastian Schaub, DVM
Dr. med. vet. DipECVDI

HOSPITAL NAME

Paseos Veterinary
Center

REFERRING VET

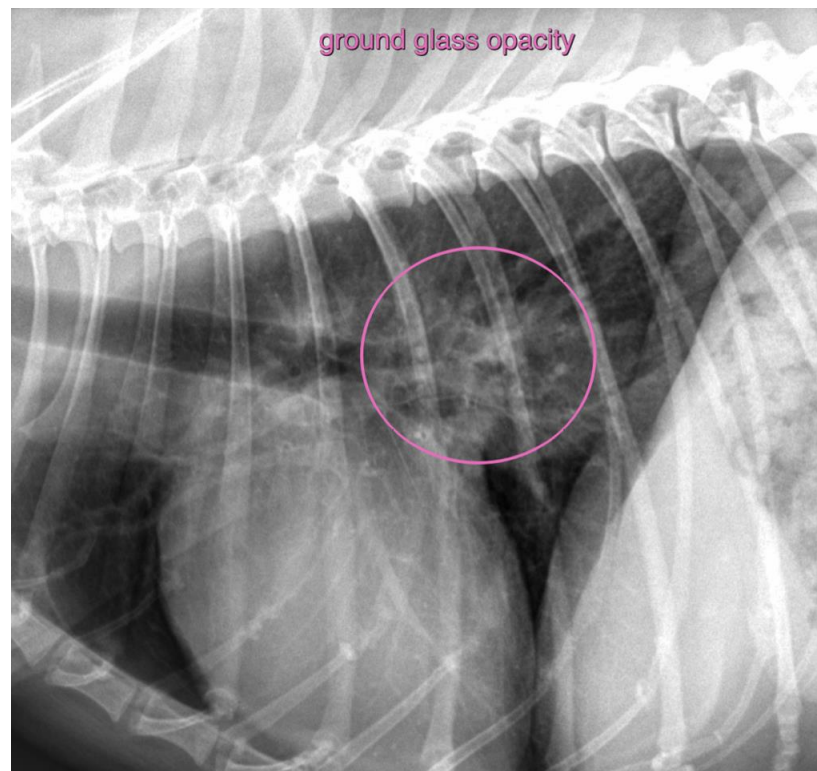
Dr. Biello, DVM

INVOICE

58834

DATE

6-14-23





PATIENT

Bella Abou

SPECIES

Canine

BREED

Beagle Mix

SEX

Female Spayed

AGE

10 Years

INTERPRETED BY

Sebastian Schaub, DVM
Dr. med. vet. DipECVDI

HOSPITAL NAME

Paseos Veterinary
Center

REFERRING VET

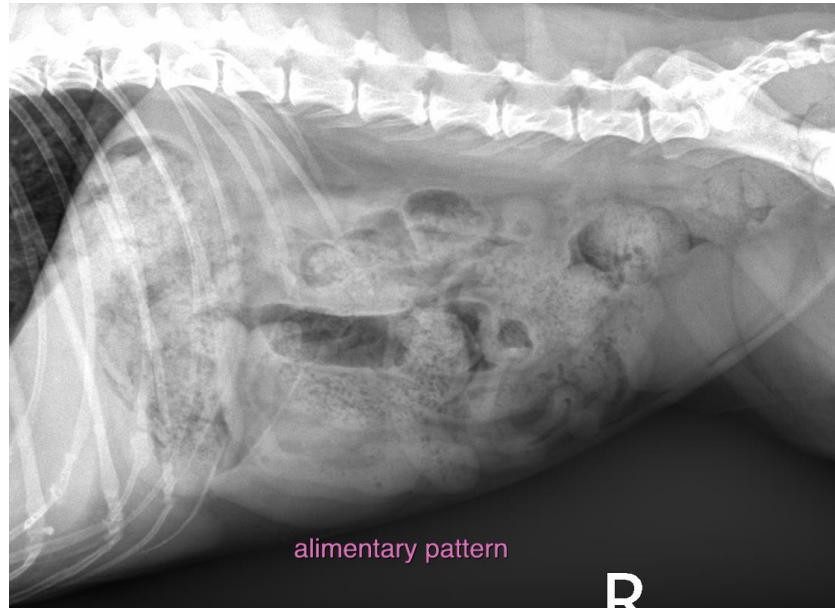
Dr. Biello, DVM

INVOICE

58834

DATE

6-14-23



The information and recommendations provided are based on the images presented by the referring veterinarian/sonographer. No evaluation can be communicated regarding pathology that was not visible in the image/video clips provided.

Thank you for this referral. If the clinical or image interpretation does not parallel your findings or if I can be of any further assistance please contact me.

Sebastian Schaub, Sebastian Schaub, DVM, Dr. med. vet. DipECVDI
info@sonopath.com