



**PATIENT PRESENTING CLINICAL SIGNS**

Alder Wisniewski Twice over the past week pt has had fits of dry honking cough that last about 10 seconds. He did a little bit of this about a year ago and has not done so since.  
Abnormal PE/Chem/CBC/UA Results: Healthy physical exam Labs pending

**SPECIES RADIOGRAPHIC STUDY OF THE THORAX**

Feline Radiographs of the thorax in three imaging planes are provided for review.

**RADIOGRAPHIC FINDINGS**

**BREED** The surrounding bony structures are within normal limits.

DSH The extrathoracic soft tissues present homogeneous without abnormalities.

The heart is of normal size and shape, there is no evidence of cardiac chamber or vascular enlargement.

**SEX** The pulmonary vasculature is within normal limits.

Neutered Male The trachea is normal in diameter and presents the anticipated course. The luminal outline of the trachea is smooth.

**AGE** Generalized mild increased visibility of the bronchial walls is appreciated.

1 Year The lung parenchyma presents the expected architecture and opacity; the intrapulmonary vascular branching is seen up to the third order lung vessels.

**INTERPRETED BY** The diaphragm is well delineated with even surface and the expected mild cranial bulging of the diaphragmatic cupola.

Sebastian Schaub, DVM  
Dr. med. vet. DipECVCI

**RADIOGRAPHIC DIAGNOSIS**

- Mild bronchial lung pattern
- No evidence of air-trapping

**HOSPITAL NAME**

Northshore  
Veterinary Hospital

**INTERPRETATION OF THE FINDINGS & FURTHER RECOMMENDATIONS**

The radiographic changes are suggestive for feline bronchial disease ("feline asthma") – commonly primary allergic in origin ± bacterial superinfection. Primary infectious causes – such as viral, parasitic, bacterial, Mycoplasma – are a consideration, but appear less likely.

**REFERRING VET**

Sophie Lee

**INVOICE**

58841

**DATE**

6-14-23



**PATIENT**

Alder Wisniewski

**SPECIES**

Feline

**BREED**

DSH

**SEX**

Neutered Male

**AGE**

1 Year

**INTERPRETED BY**

Sebastian Schaub, DVM  
Dr. med. vet. DipECVDI

**HOSPITAL NAME**

Northshore  
Veterinary Hospital

**REFERRING VET**

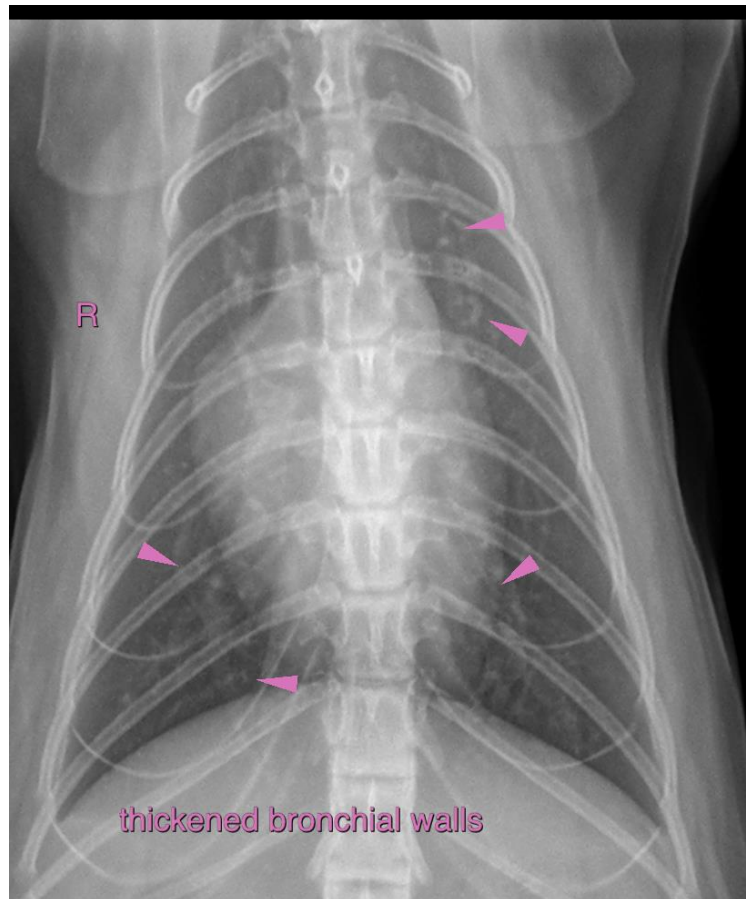
Sophie Lee

**INVOICE**

58841

**DATE**

6-14-23



The information and recommendations provided are based on the images presented by the referring veterinarian/sonographer. No evaluation can be communicated regarding pathology that was not visible in the image/video clips provided.

Thank you for this referral. If the clinical or image interpretation does not parallel your findings or if I can be of any further assistance please contact me.

**Sebastian Schaub**, Sebastian Schaub, DVM, Dr. med. vet. DipECVDI  
[info@sonopath.com](mailto:info@sonopath.com)