



PATIENT PRESENTING CLINICAL SIGNS

Ringo Michelson Suspected weight loss. Hx of mast cell tumor base of Right ear (previously removed surgically in Oct. 2021. Thoracic radiographs showed 1.6 cm nodule Right caudal lung lobe with possible second nodule Right middle lung lobe.

SPECIES COMPUTED TOMOGRAPHY OF THE THORAX

Feline A high resolution pre- and post-contrast CT study of the thorax is provided for review.

COMPUTED TOMOGRAPHIC FINDINGS

BREED The bony and surrounding soft tissue structures are within normal limits.

DSH The sternal, cranial mediastinal and tracheobronchial lymph nodes are small elongated with a normal short-to-long-axis-ratio is < 0.5, the attenuation and contrast enhancement pattern is uniform and considered within normal limits.

SEX The cardiovascular structures including the pulmonary vasculature are within normal limits.

Neutered Male Moderate thickening of the bronchial walls is appreciated, and the lung parenchyma presents multiple ill-defined regions with ground glass attenuating parenchyma

AGE Small incidental gas pockets are seen within the esophageal lumen, there is no evidence of abnormal dilation.

10 Years, 6 Months

COMPUTED TOMOGRAPHIC DIAGNOSIS

- Moderate bronchial lung pattern with a randomly distributed unstructured interstitial component

INTERPRETED BY

Sebastian Schaub, DVM
Dr. med. vet. DipECVDI

INTERPRETATION OF THE FINDINGS & FURTHER RECOMMENDATIONS

HOSPITAL NAME

Mobile Pet Imaging

The lung pattern is most consistent with inflammatory feline bronchial disease and accompanying pneumonitis, bacterial superinfection is possible here. Although bronchial carcinoma might present with a generalized thickening of the bronchial walls, I consider the odds very low and the findings are atypical for metastatic disease.

Bronchoscopy including BAL might be used as advanced diagnostic test.

REFERRING VET

Meaux

INVOICE

52422

DATE

6-13-22



PATIENT

Ringo Michelson

SPECIES

Feline

BREED

DSH

SEX

Neutered Male

AGE

10 Years, 6 Months

INTERPRETED BY

Sebastian Schaub, DVM
Dr. med. vet. DipECVDI

HOSPITAL NAME

Mobile Pet Imaging

REFERRING VET

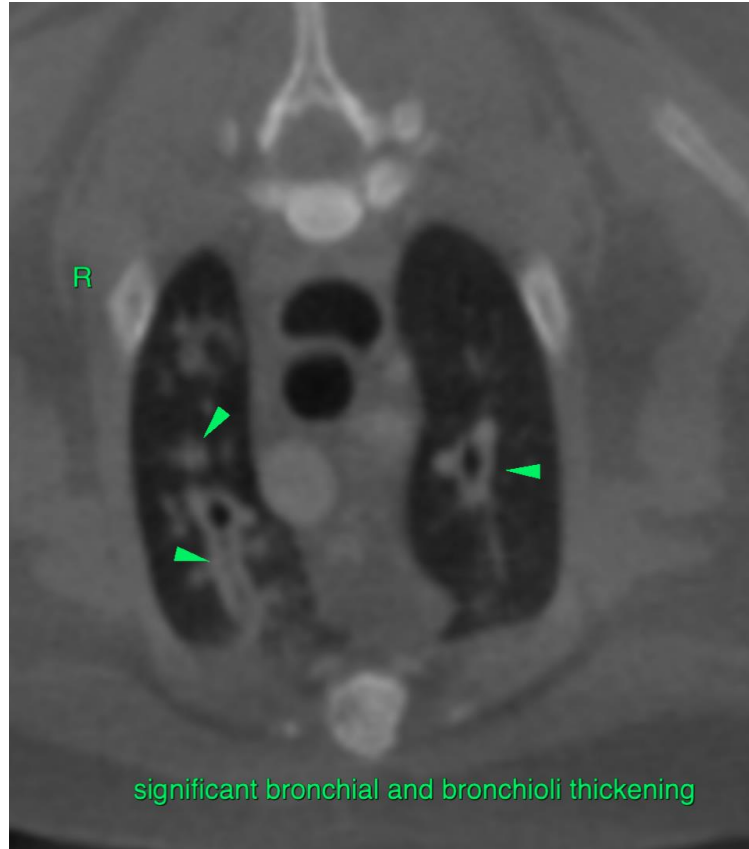
Meaux

INVOICE

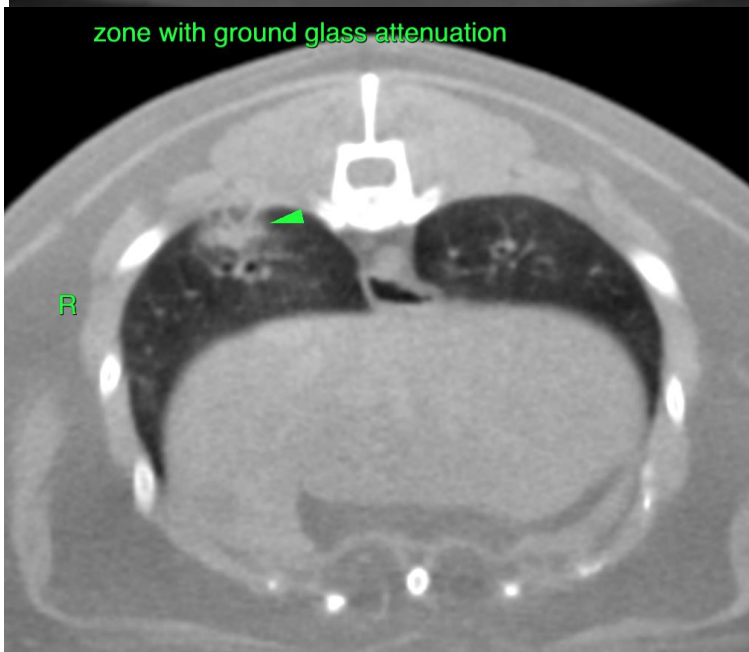
52422

DATE

6-13-22



significant bronchial and bronchioli thickening



zone with ground glass attenuation



PATIENT

Ringo Michelson

The information and recommendations provided are based on the images presented by the referring veterinarian/sonographer. No evaluation can be communicated regarding pathology that was not visible in the image/video clips provided.

SPECIES

Feline

Thank you for this referral. If the clinical or image interpretation does not parallel your findings or if I can be of any further assistance please contact me.

BREED

DSH

Sebastian Schaub, Sebastian Schaub, DVM, Dr. med. vet. DipECVDI
sebast.schaub@gmail.com

SEX

Neutered Male

AGE

10 Years, 6 Months

INTERPRETED BY

Sebastian Schaub, DVM
Dr. med. vet. DipECVDI

HOSPITAL NAME

Mobile Pet Imaging

REFERRING VET

Meaux

INVOICE

52422

DATE

6-13-22