



PATIENT

Merlin Waltz

SPECIES

Canine

BREED

Doberman Pinscher

SEX

Male Neutered

AGE

7.5 Years

INTERPRETED BY

Sebastian Schaub, DVM
Dr. med. vet. DipECVDI

HOSPITAL NAME

Friendship Springs
Veterinary Care

REFERRING VET

Trae Cutchin

INVOICE

52398

DATE

6-13-22

PRESENTING CLINICAL SIGNS

One month duration of lameness. O thinks forelimb but on exam the pelvic limb gait seem more affected. Subtle thickness in the proximal half of the gastroc tendon is noted on the right side and a very small mass(?) is palpable at the mid-point. Lameness in more than one limb is not ruled out. The stifles do not palpate as thickened but cruciate disease is not ruled out. Pt is overweight. Abnormal PE/Chem/CBC/UA Results: None

RADIOGRAPHIC STUDY OF THE STIFLE JOINTS

Radiographs of the stifle joints in two imaging planes are provided for review.

RADIOGRAPHIC FINDINGS

The osseous margins of both stifle joints are smooth. The right stifle joint presents without signs of intracapsular swelling. The left stifle joint presents a mild increased intracapsular soft tissue volume, distorting the infrapatellar fat-pad.

RADIOGRAPHIC DIAGNOSIS

- Very mild articular swelling left stifle joint
- Structural normal right stifle joint

INTERPRETATION OF THE FINDINGS & FURTHER RECOMMENDATIONS

The left stifle joint presents evidence of very mild intracapsular swelling suggestive for mild joint effusion- might be traumatic, degenerative or primary inflammatory in origin; pathology of the cranial cruciate ligament is most common, but there are no signs for accompanying degenerative changes of the periarticular osseous structures.

Check if a positive drawer sign or tibial compression test can be appreciated under general anesthesia.



PATIENT

Merlin Waltz

SPECIES

Canine

BREED

Doberman Pinscher

SEX

Male Neutered

AGE

7.5 Years

INTERPRETED BY

Sebastian Schaub, DVM
Dr. med. vet. DipECVDI

HOSPITAL NAME

Friendship Springs
Veterinary Care

REFERRING VET

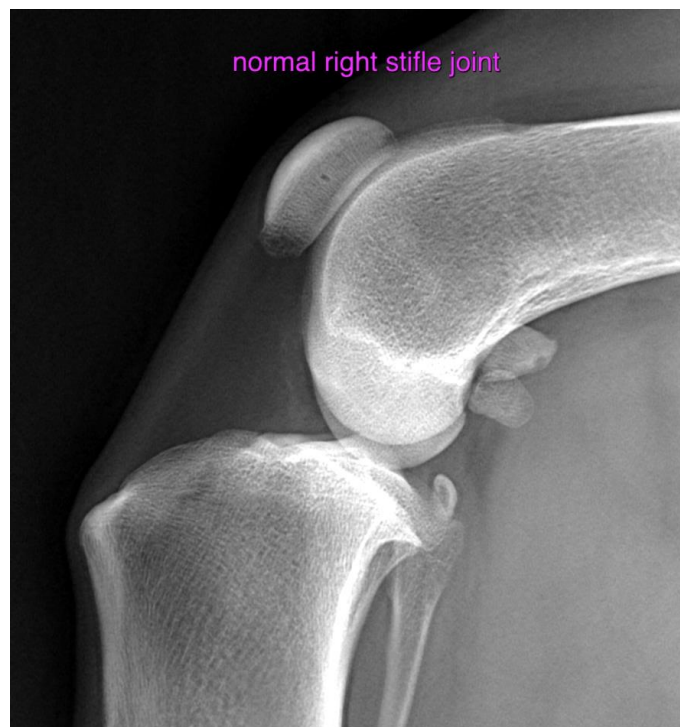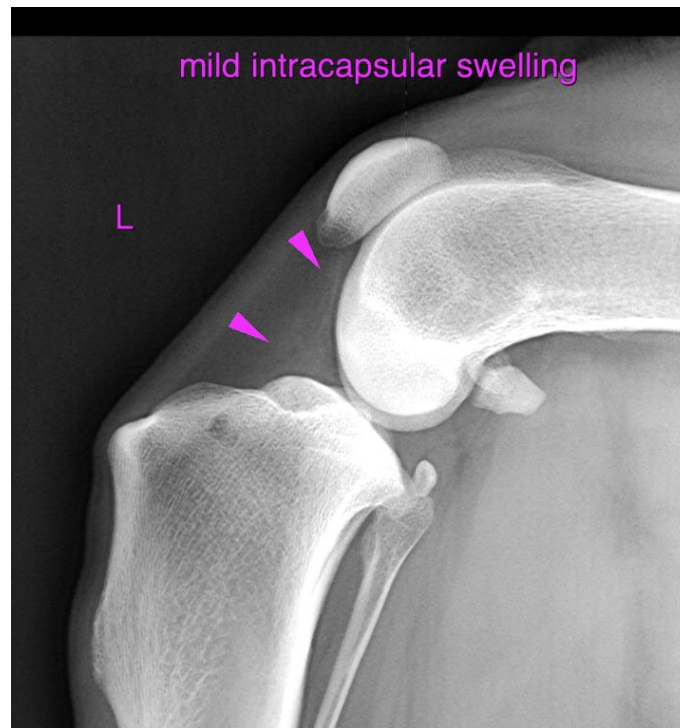
Trae Cutchin

INVOICE

52398

DATE

6-13-22





PATIENT

Merlin Waltz

SPECIES

Canine

BREED

Doberman Pinscher

SEX

Male Neutered

AGE

7.5 Years

INTERPRETED BY

Sebastian Schaub, DVM
Dr. med. vet. DipECVDI

HOSPITAL NAME

Friendship Springs
Veterinary Care

REFERRING VET

Trae Cutchin

INVOICE

52398

DATE

6-13-22

The information and recommendations provided are based on the images presented by the referring veterinarian/sonographer. No evaluation can be communicated regarding pathology that was not visible in the image/video clips provided.

Thank you for this referral. If the clinical or image interpretation does not parallel your findings or if I can be of any further assistance please contact me.

Sebastian Schaub, Sebastian Schaub, DVM, Dr. med. vet. DipECVDI
sebast.schaub@gmail.com