



**PATIENT**

Luna Stephens

**PRESENTING CLINICAL SIGNS**

Gave birth for 4 puppies 4 weeks ago. Vomiting and diarrhea started overnight. Lethargic. Temp. = 39.3 | HR = 120bpm | RR = 60 The last left mammary gland is swollen, painful and hot. Ate last night. No history of garbage exposure or diet change.

**SPECIES**

Canine

Abnormal PE/Chem/CBC/UA Results: Blood work indicate stress glucose, mild dehydration, mild decrease in K, otherwise unremarkable Normal Ca,

**BREED**

Bulldog, French

**RADIOGRAPHIC STUDY OF THE ABDOMEN**

Radiographs of the abdomen three imaging planes are provided for review.

**RADIOGRAPHIC FINDINGS**

The surrounding bony structures are within normal limits.

**SEX**

Female

The mammary complexes along the ventral abdominal wall are prominent - significant swelling of the caudal mammary complexes is appreciated.

The serosal detail is maintained throughout the peritoneal and retroperitoneal space.

The liver is appropriate in position, size and presents uniform opacity.

**AGE**

3 Years

The splenic head is in the anticipated position and within normal limits for size and opacity. The splenic body and tail are considered normal for position, size, shape and opacity.

**INTERPRETED BY**

Sebastian Schaub, DVM  
Dr. med. vet. DipECVDI

Both kidneys are seen and present with normal size, shape, delineation and opacity. The urinary bladder is in its anticipated position. No radiopaque calculi are noted throughout the upper and lower urinary tract.

The stomach is in its anticipated position and contains a small amount of gas.

**HOSPITAL NAME**

St. Catherine's Animal  
Hospital

The small intestinal loops are of even diameter and non-dilated, a small amount of gas is seen within the small intestinal loops and considered within normal limits.

The colon is seen in the expected position and contains a small amount of foamy fecal material.

**RADIOGRAPHIC DIAGNOSIS**

- Swelling caudal mammary complexes
- Empty gastrointestinal tract

**REFERRING VET**

Dr. Bekhit

**INTERPRETATION OF THE FINDINGS & FURTHER RECOMMENDATIONS**

**INVOICE**

52429

The empty gastrointestinal tract in combination with the presenting clinical signs is consistent with gastroenteritis. There is no evidence of radiopaque foreign material or signs for gastrointestinal mechanical obstruction.

The swelling of the mammary complex might still be within limits due to lactation, however, rule out developing mastitis.

**DATE**

6-13-22



**PATIENT**

Luna Stephens

**SPECIES**

Canine

**BREED**

Bulldog, French

**SEX**

Female

**AGE**

3 Years

**INTERPRETED BY**

Sebastian Schaub, DVM  
Dr. med. vet. DipECVDI

**HOSPITAL NAME**

St. Catherine's Animal  
Hospital

**REFERRING VET**

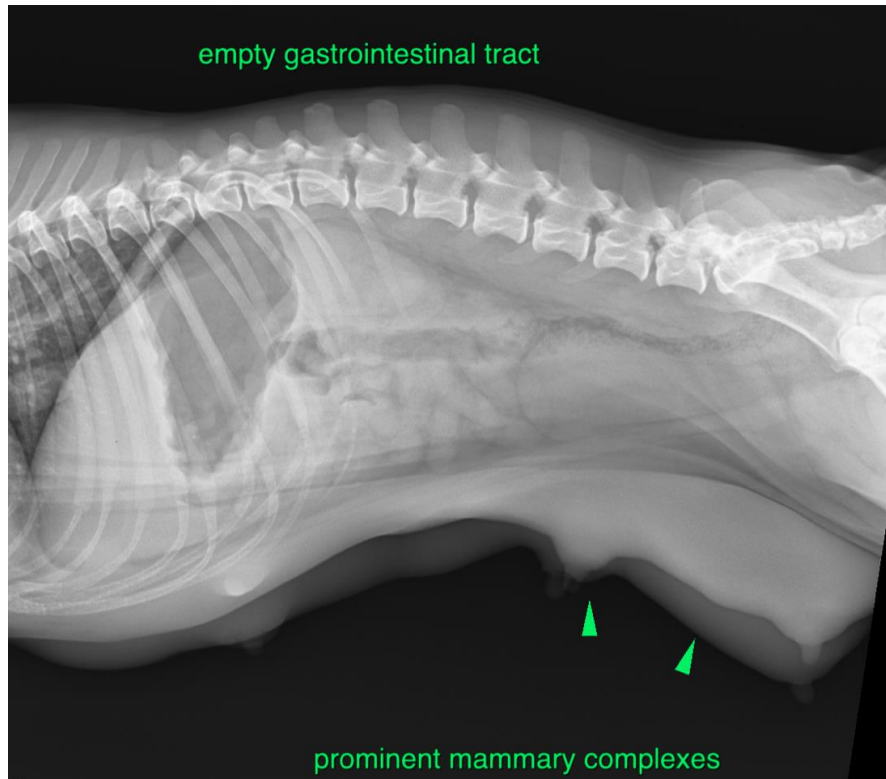
Dr. Bekhit

**INVOICE**

52429

**DATE**

6-13-22



The information and recommendations provided are based on the images presented by the referring veterinarian/sonographer. No evaluation can be communicated regarding pathology that was not visible in the image/video clips provided.

Thank you for this referral. If the clinical or image interpretation does not parallel your findings or if I can be of any further assistance please contact me.

**Sebastian Schaub**, Sebastian Schaub, DVM, Dr. med. vet. DipECVDI  
sebast.schaub@gmail.com