



**PATIENT**

Lacy DeMicco

**PRESENTING CLINICAL SIGNS**

Intermittent Coughing

**SPECIES**

Canine

**RADIOGRAPHIC STUDY OF THE THORAX**

A right lateral view of the thorax is provided for review.

**BREED**

Bichon Frise

**RADIOGRAPHIC FINDINGS**

The vertebral endplates T5/T6 present moderate spondylosis formation. At the caudal aspect of the humeral heads, mild osteophyte new bone formation is appreciated.

The extrathoracic soft tissues present homogeneous without abnormalities.

The heart is of normal size and shape, there is no evidence of cardiac chamber or vascular enlargement. The pulmonary vasculature is within normal limits.

**SEX**

Female/sp

The cervical tracheal segment presents a mild to moderate decreased height.

Generalized mild to moderate thickening of the bronchial walls is appreciated.

**AGE**

15 Years

The lung parenchyma presents the expected architecture and opacity; the intrapulmonary vascular branching is seen up to the third order lung vessels.

The diaphragm is well delineated with even surface and the expected mild cranial bulging of the diaphragmatic cupola.

**INTERPRETED BY**

Sebastian Schaub, DVM  
Dr. med. vet. DipECVDI

**RADIOGRAPHIC DIAGNOSIS**

- Mild bronchial lung pattern
- Mild tracheal collapse cervical segment
- Mild degenerative osteoarthritis shoulder joints bilaterally
- Spondylosis deformans

**HOSPITAL NAME**

New Bridge  
Veterinary Practice

**INTERPRETATION OF THE FINDINGS & FURTHER RECOMMENDATIONS**

The bronchial lung pattern is indicative for bronchitis, and I consider the odds for inflammatory non-infectious bronchitis (e.g. allergic, eosinophilic, lymphocytic plasmocytic, mixed) higher than for infectious bronchitis (viral, bacterial, parasitic).

**REFERRING VET**

Dr. Abina Glennon

The mild tracheal collapse might contribute to the clinical signs as well.

**INVOICE**

52423

**DATE**

6-13-22



**PATIENT**

Lacy DeMicco

**SPECIES**

Canine

**BREED**

Bichon Frise

**SEX**

Female/sp

**AGE**

15 Years

**INTERPRETED BY**

Sebastian Schaub, DVM  
Dr. med. vet. DipECVDI

**HOSPITAL NAME**

New Bridge  
Veterinary Practice

**REFERRING VET**

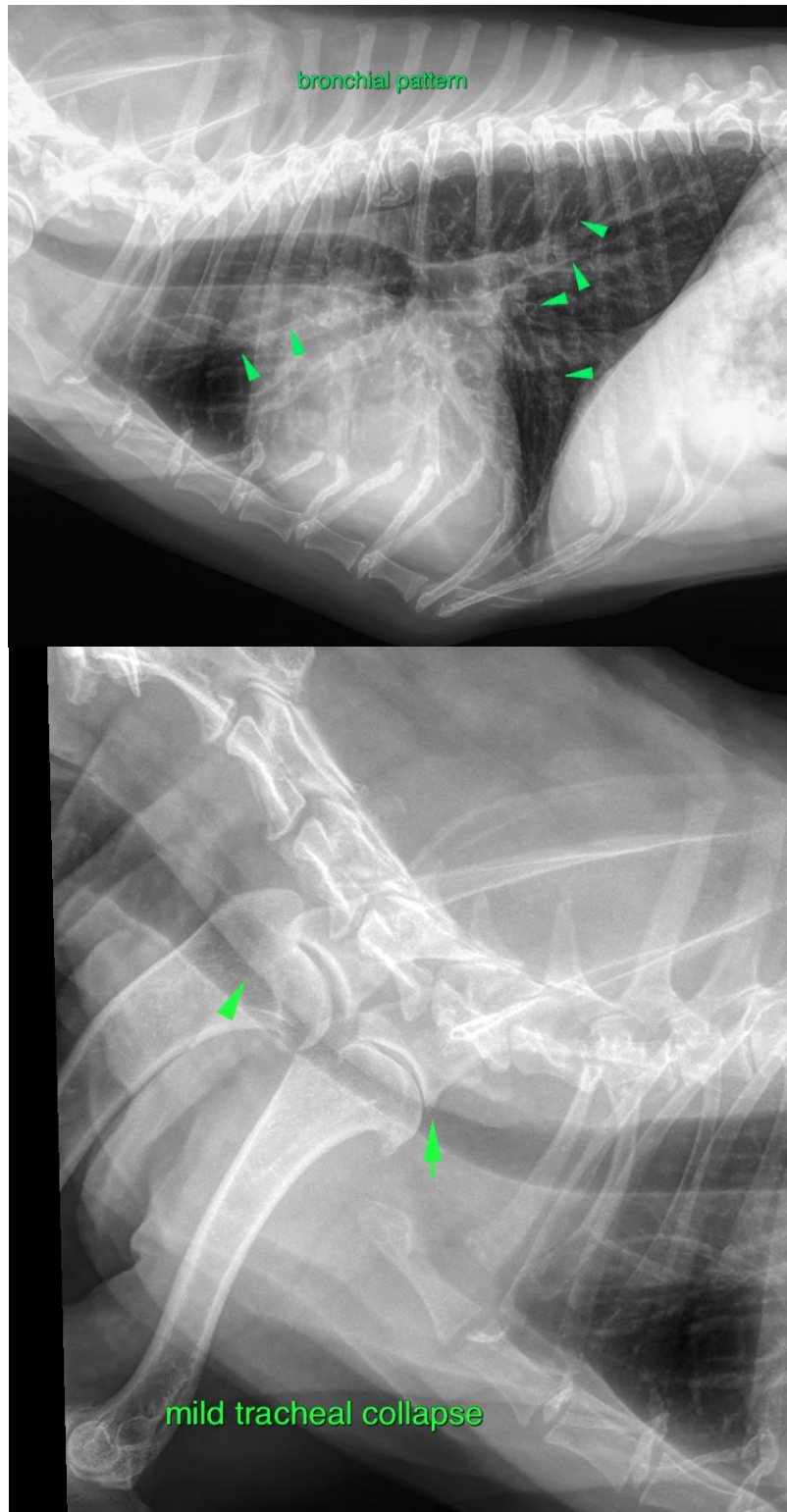
Dr. Abina Glennon

**INVOICE**

52423

**DATE**

6-13-22





**PATIENT**

Lacy DeMicco

**SPECIES**

Canine

The information and recommendations provided are based on the images presented by the referring veterinarian/sonographer. No evaluation can be communicated regarding pathology that was not visible in the image/video clips provided.

**BREED**

Bichon Frise

Thank you for this referral. If the clinical or image interpretation does not parallel your findings or if I can be of any further assistance please contact me.

**Sebastian Schaub**, Sebastian Schaub, DVM, Dr. med. vet. DipECVDI  
sebast.schaub@gmail.com

**SEX**

Female/sp

**AGE**

15 Years

**INTERPRETED BY**

Sebastian Schaub, DVM  
Dr. med. vet. DipECVDI

**HOSPITAL NAME**

New Bridge  
Veterinary Practice

**REFERRING VET**

Dr. Abina Glennon

**INVOICE**

52423

**DATE**

6-13-22