



**PATIENT PRESENTING CLINICAL SIGNS**

LG Carruthers Having reluctance to jump and go up the stairs. No trouble going down. No trouble running. No neurological deficits  
 Abnormal PE/Chem/CBC/UA Results: Mild hypokalemia Mild neutropenia Retrovirus status negative

**SPECIES**

Feline

**RADIOGRAPHIC STUDY OF THE STIFLE JOINTS**

Radiographs of the pelvis and the stifle joints are provided for review.

**BREED**

DSH

**RADIOGRAPHIC FINDINGS**

The lumbosacral intervertebral disc space is collapsed and the respective vertebral endplates present moderate spondylosis formation and sclerosis of the subchondral bone.

**SEX**

The osseous and surrounding soft tissue structures of the pelvis are within normal limits. Both coxofemoral joints present smooth osseous margins and congruent joint spaces.

MN

Small gas bubbles are seen in the subcutaneous tissue at the proximolateral aspect of the right thigh musculature – suspect preceding injection.

**AGE**

8 Years

The stifle joints present smooth osseous margins and without evidence of intracapsular swelling.

In the craniocaudal view, the musculature of the left crus presents a heterogeneous soft tissue opacity – consistent with wet-fur artefact.

**INTERPRETED BY**

Sebastian Schaub, DVM  
 Dr. med. vet. DipECVDI

**RADIOGRAPHIC DIAGNOSIS**

- Chronic discopathy L7/S1 with osseous remodeling of the respective vertebral endplates and ventral spondylosis formation
- Normal pelvis including coxofemoral joints
- Normal stifle joints bilaterally

**HOSPITAL NAME**

Balmy Beach Pet Hospital

**INTERPRETATION OF THE FINDINGS & FURTHER RECOMMENDATIONS**

The chronic discopathy of the lumbosacral junction might be associated with compressive myelopathy (degenerative lumbosacral stenosis) and can be a source for the described clinical signs. Cross-sectional imaging can be considered as advanced diagnostic tool, to confirm the diagnosis.

**REFERRING VET**

Dr. Singh

The osseous structures of the pelvis and the stifle joints present without abnormalities.

**INVOICE**

52413

**DATE**

6-13-22



**PATIENT**

LG Carruthers

**SPECIES**

Feline

**BREED**

DSH

**SEX**

MN

**AGE**

8 Years

**INTERPRETED BY**

Sebastian Schaub, DVM  
Dr. med. vet. DipECVDI

**HOSPITAL NAME**

Balmy Beach Pet  
Hospital

**REFERRING VET**

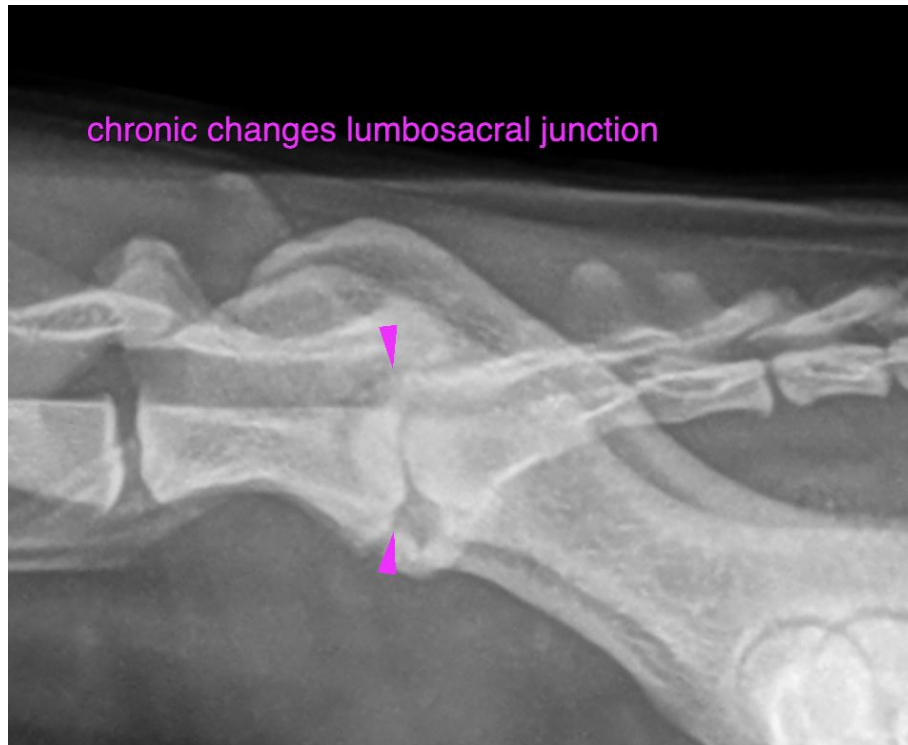
Dr. Singh

**INVOICE**

52413

**DATE**

6-13-22



The information and recommendations provided are based on the images presented by the referring veterinarian/sonographer. No evaluation can be communicated regarding pathology that was not visible in the image/video clips provided.

Thank you for this referral. If the clinical or image interpretation does not parallel your findings or if I can be of any further assistance please contact me.

**Sebastian Schaub**, Sebastian Schaub, DVM, Dr. med. vet. DipECVDI  
sebast.schaub@gmail.com