



PATIENT

Jerome Maingot

SPECIES

Canine

BREED

Maltese

SEX

Female Spayed

AGE

8

INTERPRETED BY

Sebastian Schaub, DVM
Dr. med. vet. DipECVDI

HOSPITAL NAME

Lakeshore Woods
Animal Hospital

REFERRING VET

Dr. Sam Masoud

INVOICE

52416

DATE

6-13-22

PRESENTING CLINICAL SIGNS

Acute onset of bloody diarrhea, less active, eat this morning, no vomiting
Abnormal PE/Chem/CBC/UA Results: periodontal disease grade 4/4, moderate abdominal distension and pain during palpation, perineal area soiled with bloody diarrhea, keep dripping bloody liquid fecal material during exam, bloodwork unremarkable, CPLi: normal, O&P normal, Giardia Positive, sent home with supportive medication.

RADIOGRAPHIC STUDY OF THE ABDOMEN

Radiographs of the abdomen in three imaging planes are provided for review. Radiographs are provided in JPEG file format.

RADIOGRAPHIC FINDINGS

The surrounding bony structures are within normal limits.

No abnormalities of the extraabdominal soft tissues are noted. The abdominal wall is smooth and thin.

The serosal detail is maintained throughout the peritoneal and retroperitoneal space.

The liver is appropriate in position, size and presents uniform opacity.

The splenic head is in the anticipated position and within normal limits for size and opacity. The splenic body and tail are considered normal for position, size, shape and opacity.

Both kidneys are seen and present with normal size, shape, delineation and opacity. The urinary bladder is in its anticipated position. No radiopaque calculi are noted throughout the upper and lower urinary tract.

The stomach is in its anticipated position and presents normal content.

The small intestinal loops are of even diameter, non-dilated and appear rigid.

The colon is seen in the expected position and is mildly distended by gas. The colonic wall is mildly corrugated.

RADIOGRAPHIC DIAGNOSIS

- Empty and mildly corrugated colon
- Hypodynamic appears small intestinal loops

INTERPRETATION OF THE FINDINGS & FURTHER RECOMMENDATIONS

The empty and mildly corrugated colon in combination with adynamic appearing small intestinal loops are suggestive for enteritis/colitis – Giardia infection has already been confirmed, regarding the history. There is no evidence of radiopaque foreign material or signs for gastrointestinal mechanical obstruction. If clinical signs are refractory to therapy, recommend a complete abdominal ultrasound examination.



PATIENT

Jerome Maingot

SPECIES

Canine

BREED

Maltese

SEX

Female Spayed

AGE

8

INTERPRETED BY

Sebastian Schaub, DVM
Dr. med. vet. DipECVDI

HOSPITAL NAME

Lakeshore Woods
Animal Hospital

REFERRING VET

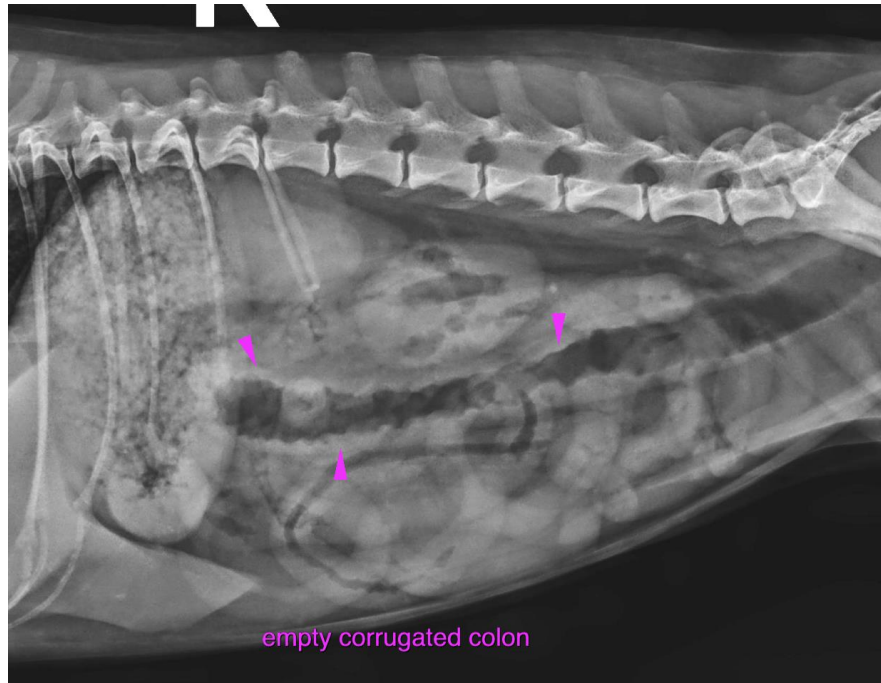
Dr. Sam Masoud

INVOICE

52416

DATE

6-13-22



The information and recommendations provided are based on the images presented by the referring veterinarian/sonographer. No evaluation can be communicated regarding pathology that was not visible in the image/video clips provided.

Thank you for this referral. If the clinical or image interpretation does not parallel your findings or if I can be of any further assistance please contact me.

Sebastian Schaub, Sebastian Schaub, DVM, Dr. med. vet. DipECVDI
sebast.schaub@gmail.com