



PATIENT

Doris Giles

PRESENTING CLINICAL SIGNS

Chronic allergies with bilateral ocular and nasal discharge. Suspected nasal turbinates infection.

COMPUTED TOMOGRAPHY OF THE SKULL

SPECIES

Canine

A high resolution pre- and post-contrast CT study of the skull is provided for review.

BREED

German Shepherd
Mix

COMPUTED TOMOGRAPHIC FINDINGS

Alveolar crest of the tooth element 404 presents with a focal geographic osteolytic lesion dorsally, perforating the dorsal cortex. Moderate horizontal bone loss level with the mandibular incisors is appreciated.

The nasal cavity presents the expected aerated spaces between thin & even conchae and turbinates with smooth mucosal lining.

Both temporomandibular joints present congruent joint spaces with even subchondral bone surfaces and are considered within normal limits.

SEX

FS

Both tympanic bullae are aerated, the mucosal lining is not seen, the bony wall is smooth and thin. The external ear canals are within normal limits.

AGE

7

The brain presents no deviation from normal anatomy and symmetry. The brain parenchyma is homogeneous and within normal limits for attenuation and distribution of contrast enhancement. The ventricular system is non-dilated and symmetric.

INTERPRETED BY

Sebastian Schaub, DVM
Dr. med. vet. DipECVDI

COMPUTED TOMOGRAPHIC DIAGNOSIS

- Periodontal disease 404 and mandibular incisors
- Normal nasal cavity

HOSPITAL NAME

Scottsdale Veterinary
Clinic

INTERPRETATION OF THE FINDINGS & FURTHER RECOMMENDATIONS

No abnormalities of the nasal cavity are appreciated and given the history of nasal discharge the presumptive diagnosis is non-specific rhinitis (e.g. lymphocytic plasmocytic, eosinophilic). Rhinoscopy including biopsy might be used as advanced diagnostic tests.

REFERRING VET

Dr. Kerby

INVOICE

52412

DATE

6-11-22



PATIENT

Doris Giles

SPECIES

Canine

BREED

German Shepherd
Mix

SEX

FS

AGE

7

INTERPRETED BY

Sebastian Schaub, DVM
Dr. med. vet. DipECVDI

HOSPITAL NAME

Scottsdale Veterinary
Clinic

REFERRING VET

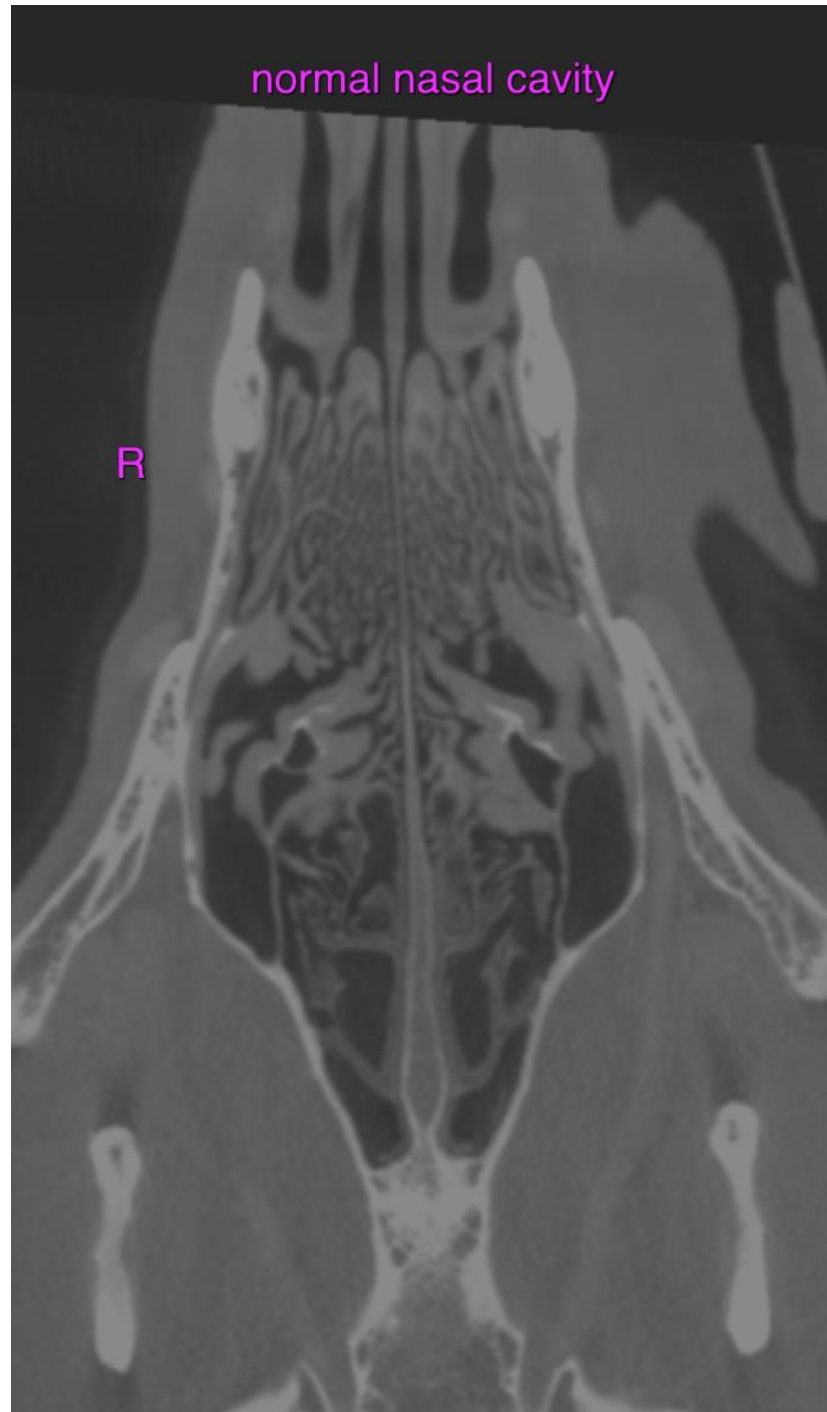
Dr. Kerby

INVOICE

52412

DATE

6-11-22





PATIENT

Doris Giles

SPECIES

Canine

BREED

German Shepherd
Mix

SEX

FS

AGE

7

INTERPRETED BY

Sebastian Schaub, DVM
Dr. med. vet. DipECVDI

HOSPITAL NAME

Scottsdale Veterinary
Clinic

REFERRING VET

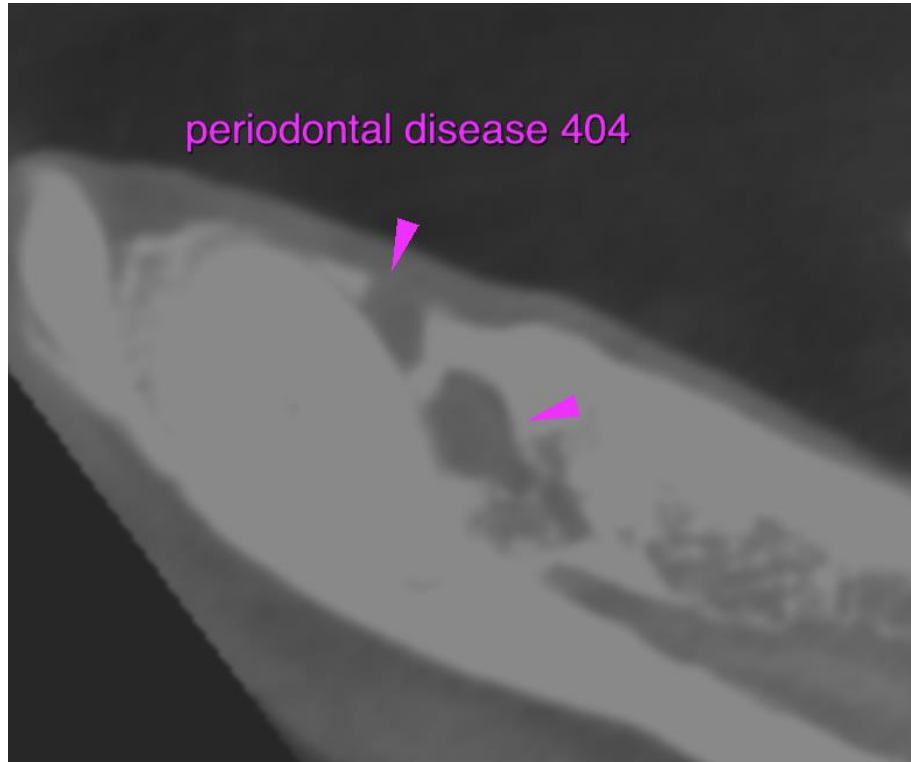
Dr. Kerby

INVOICE

52412

DATE

6-11-22



The information and recommendations provided are based on the images presented by the referring veterinarian/sonographer. No evaluation can be communicated regarding pathology that was not visible in the image/video clips provided.

Thank you for this referral. If the clinical or image interpretation does not parallel your findings or if I can be of any further assistance please contact me.

Sebastian Schaub, Sebastian Schaub, DVM, Dr. med. vet. DipECVDI
sebast.schaub@gmail.com