



**PATIENT**

**PRESENTING CLINICAL SIGNS**

Chloe Alves Da Mota

cluster seizures that motivated hospitalization Had 1st seizure in April 2022  
Abnormal PE/Chem/CBC/UA Results: There is a mild tendency to lean towards the left when walking in straight line Cranial nerves: Mildly decreased response menace OU, questionable worse OS CSF analysis is normal

**SPECIES**

Canine

**COMPUTED TOMOGRAPHY OF THE SKULL**

A plain CT study of the skull in a bone and soft tissue reconstruction is provided for review.

**BREED**

Miniature Schnauzer

**COMPUTED TOMOGRAPHIC FINDINGS**

Triadan 210 presents a moderate widening of the periodontal space. Triadan 109 presents a periapical widening of the periodontal space of the palatine root.

**SEX**

Female Spayed

In the left nasal cavity, a mild to moderate amount of fluid attenuating material is attached to the nasal mucosal lining. Mild to moderate destruction of the nasal conchal structures is appreciated, L>R.

**AGE**

5 Years, 10 Months

Both temporomandibular joints present congruent joint spaces with even subchondral bone surfaces and are considered within normal limits.

Both tympanic bullae are aerated, the mucosal lining is not seen, the bony wall is smooth and thin. The external ear canals are within normal limits.

**INTERPRETED BY**

Sebastian Schaub, DVM  
Dr. med. vet. DipECVDI

The brain presents no deviation from normal anatomy and symmetry. The brain parenchyma is homogeneous and within normal limits for attenuation. The ventricular system is non-dilated and symmetric. Small well-defined roundish depressions of the inner surface of the parietal bone bilaterally are appreciated. The remainder of the bones of the calvarium present smooth margins with the expected trabecular pattern of the diploe.

**HOSPITAL NAME**

Animal Health Partners

The submandibular and medial retropharyngeal lymph nodes are small and elongated with a normal short-to-long-axis-ratio is < 0.5, the attenuation pattern is uniform.

Multiple small gas inclusions are seen in the musculature caudal to the occipital bone and within the ventral aspect of the dural tube at the same level – suspect preceding CSF puncture.

**REFERRING VET**

Dr. Edouard Marchal

**COMPUTED TOMOGRAPHIC DIAGNOSIS**

- Mild destructive rhinitis
- Periodontal disease 109 and 210
- Normal calvarium – the small depressions in combination with the MRI findings are compatible with small islets of fatty bone marrow

**INVOICE**

52409

**INTERPRETATION OF THE FINDINGS & FURTHER RECOMMENDATIONS**

No underlying cause for the mild destructive rhinitis is appreciated – such as oronasal fistula – and the presumptive diagnosis is non-specific rhinitis (e.g. eosinophilic, lymphocytic plasmocytic).

**DATE**

6-11-22

No additional clinically relevant abnormalities are appreciated. The small depressions of the parietal bone – T1 hyperintense in the MR study – indicate small zones of fat – and are considered incidental.



**PATIENT**

Chloe Alves Da Mota

**SPECIES**

Canine

**BREED**

Miniature Schnauzer

**SEX**

Female Spayed

**AGE**

5 Years, 10 Months

**INTERPRETED BY**

Sebastian Schaub, DVM  
Dr. med. vet. DipECVDI

**HOSPITAL NAME**

Animal Health  
Partners

**REFERRING VET**

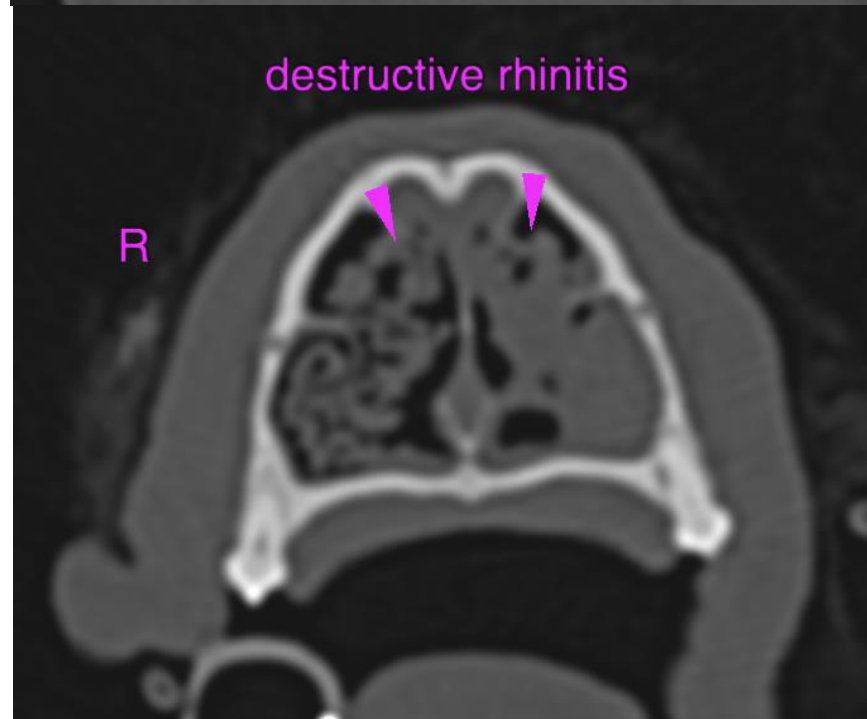
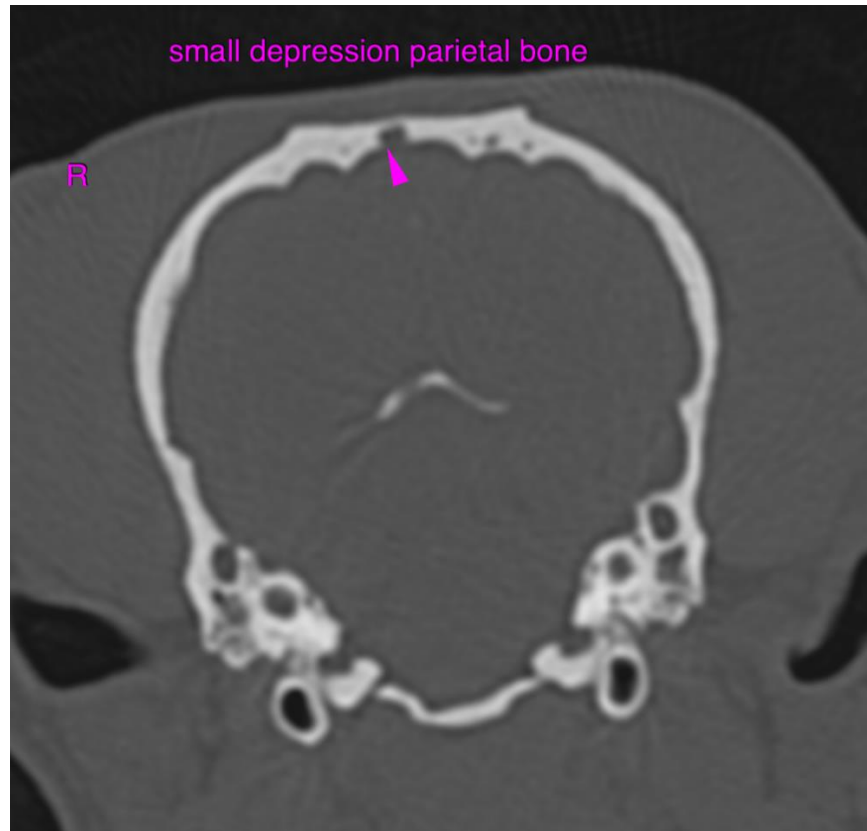
Dr. Edouard Marchal

**INVOICE**

52409

**DATE**

6-11-22





**PATIENT**

Chloe Alves Da Mota

**SPECIES**

Canine

**BREED**

Miniature Schnauzer

**SEX**

Female Spayed

**AGE**

5 Years, 10 Months

**INTERPRETED BY**

Sebastian Schaub, DVM  
Dr. med. vet. DipECVDI

**HOSPITAL NAME**

Animal Health  
Partners

**REFERRING VET**

Dr. Edouard Marchal

**INVOICE**

52409

**DATE**

6-11-22

The information and recommendations provided are based on the images presented by the referring veterinarian/sonographer. No evaluation can be communicated regarding pathology that was not visible in the image/video clips provided.

Thank you for this referral. If the clinical or image interpretation does not parallel your findings or if I can be of any further assistance please contact me.

**Sebastian Schaub**, Sebastian Schaub, DVM, Dr. med. vet. DipECVDI  
sebast.schaub@gmail.com