

**PATIENT**

Turner Anzevui

**PRESENTING CLINICAL SIGNS**

Pt presented for neuter. Upon sedation, noted upper left deciduous canine tooth present and appears grossly normal. All the rest of teeth (adult) are eroded and chipped with moderate tartar and much dentin exposed. Adult canines are mobile. r/o Enamel and dental hypoplasia. Per o, pt not having any difficulty/sensitivity eating.

**SPECIES**

Canine

Abnormal PE/Chem/CBC/UA Results: BW done 5/23: hemoglobin (13.2) and hematocrit (38.2) on low end of normal, mild increase in SDMA (15). PCV on sx day: 70, TP: 5.6.

**BREED**

Shepherd Mix

**RADIOGRAPHIC STUDY OF THE LEFT UPPER JAW QUADRANT**

Intraoral radiographs of the left upper dental arcade are provided for review.

**SEX**

NM

**RADIOGRAPHIC FINDINGS**

The crowns of triadan 203, 204 and 206 present a heterogeneous density and irregular - mild undulating - surface. The root of triadan 204 is abnormally shaped with abnormal significant tapering in the mid and distal segment. The remainder of the dentition present with the expected shape of the roots.

**AGE**

6 Months

**RADIOGRAPHIC DIAGNOSIS**

- Dysplastic triadan 204
- Suspect enamel dysplasia

**INTERPRETED BY**

Sebastian Schaub, DVM  
Dr. med. vet. DipECVDI

**INTERPRETATION OF THE FINDINGS & FURTHER RECOMMENDATIONS**

The radiographic changes in combination with the presenting clinical signs are suggestive for enamel dysplasia - can be caused by distemper infection or pyrexia period between 8-14 weeks of age. An inherited disorder with hypoplasia or hypocalcification of the enamel matrix is a potential as well.

**HOSPITAL NAME**

The Pet Hospital of  
Stratford

**REFERRING VET**

Dr. Robert Bashkin

**INVOICE**

52244

**DATE**

6-1-22



**PATIENT**

Turner Anzevui

**SPECIES**

Canine

**BREED**

Shepherd Mix

**SEX**

NM

**AGE**

6 Months

**INTERPRETED BY**

Sebastian Schaub, DVM  
Dr. med. vet. DipECVDI

**HOSPITAL NAME**

The Pet Hospital of  
Stratford

**REFERRING VET**

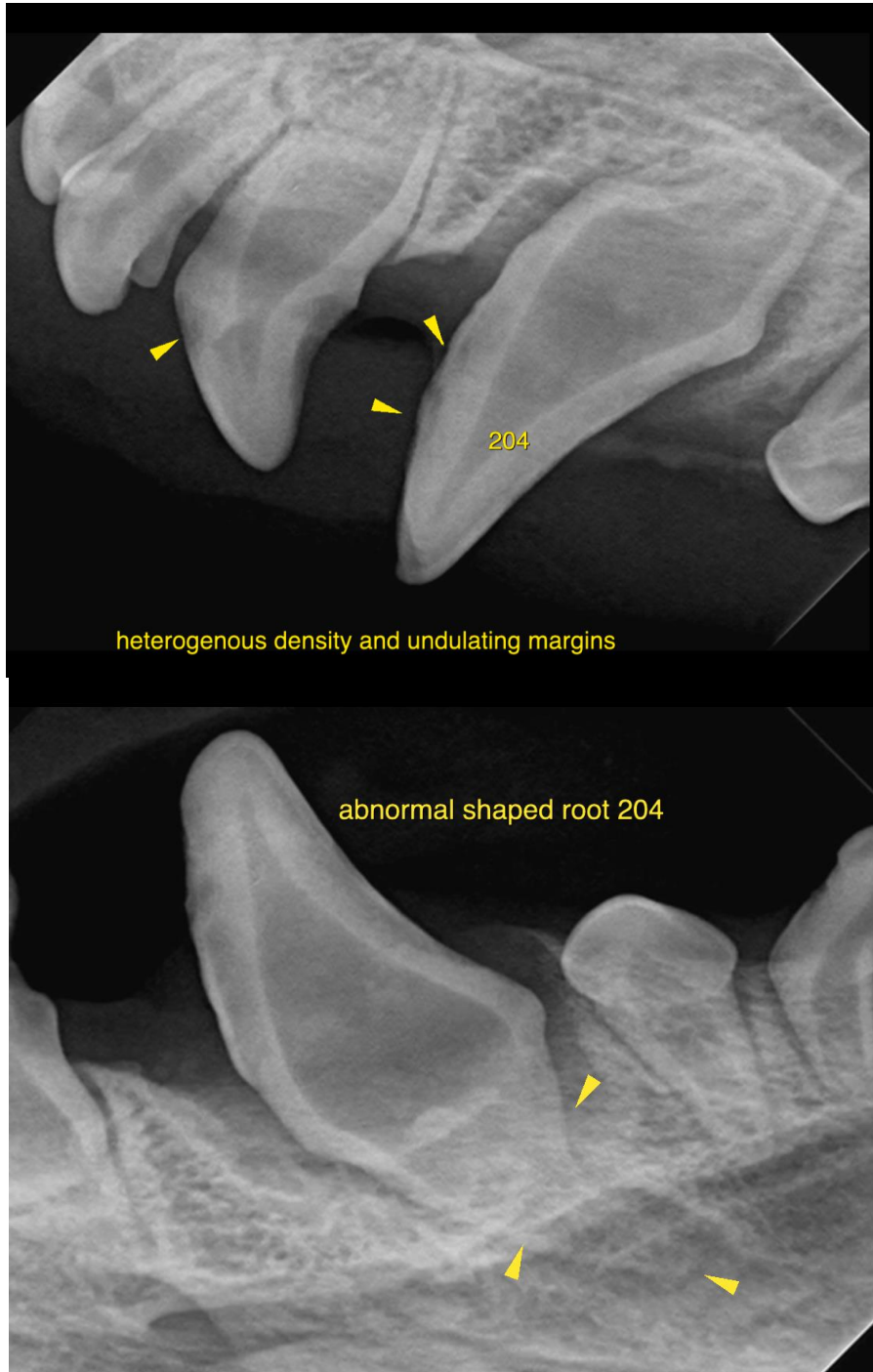
Dr. Robert Bashkin

**INVOICE**

52244

**DATE**

6-1-22





**PATIENT**

Turner Anzevui

The information and recommendations provided are based on the images presented by the referring veterinarian/sonographer. No evaluation can be communicated regarding pathology that was not visible in the image/video clips provided.

**SPECIES**

Canine

Thank you for this referral. If the clinical or image interpretation does not parallel your findings or if I can be of any further assistance please contact me.

**BREED**

Shepherd Mix

**Sebastian Schaub**, Sebastian Schaub, DVM, Dr. med. vet. DipECVDI  
sebast.schaub@gmail.com

**SEX**

NM

**AGE**

6 Months

**INTERPRETED BY**

Sebastian Schaub, DVM  
Dr. med. vet. DipECVDI

**HOSPITAL NAME**

The Pet Hospital of  
Stratford

**REFERRING VET**

Dr. Robert Bashkin

**INVOICE**

52244

**DATE**

6-1-22