



PATIENT PRESENTING CLINICAL SIGNS

Maliki Denzel dog fight wounds - hindlimb fx and perineal hernia repaired 1 week ago - now large seroma has developed with suspected herniation - question: hernia inguinal or obturator? cat is clinically well
Abnormal PE/Chem/CBC/UA Results: mild anaemia - otherwise normal

SPECIES COMPUTED TOMOGRAPHY OF THE ABDOMEN

Feline A pre- and post-contrast CT study of the abdomen in a soft tissue and bone reconstruction is provided for review.

BREED COMPUTED TOMOGRAPHIC FINDINGS

DSH The serosal fat presents normal attenuation behavior. There is no evidence of peritoneal effusion or peritonitis.

SEX Both kidneys present within normal limits for size, shape and organ architecture. After contrast administration a bilaterally symmetric and uniform nephro- and pyelogram is noted.

FE The adrenal glands are within normal limits for size, shape and organ architecture.

AGE Both liver and spleen present with normal shape, even surface, uniformly attenuating parenchyma and homogeneous contrast enhancement, unremarkable.

20 Weeks The pancreas is evenly contoured, the pancreatic parenchyma is homogeneous and presents uniform contrast enhancement.

INTERPRETED BY The position, delineation, wall and content of the gastrointestinal tract are considered within normal limits throughout.

Sebastian Schaub, DVM
Dr. med. vet. DipECVDI

A linear mineralized body is seen in the caudal aspect of the left iliopsoas muscle, level with S1, measuring 7 mm in length. Along the left hypaxial musculature L5 to S1, multiple small gas inclusions are appreciated.

HOSPITAL NAME

Advanced Veterinary
Imaging

In the midline, the ventral abdominal wall is mildly irregular marginated with a small interspersed stippled material (surgical suture material). The right caudoventral abdominal wall, just cranial to the femoral canal presents a small nodular irregularity

In the subcutaneous tissue in the inguinal region bilaterally, a moderate to marked amount of fluid attenuating material is appreciated, extending cranially along the caudoventral abdominal wall up to the level of L6.

REFERRING VET

Eamon The adductor muscles at the medial aspect of the right thigh are irregularly marginated with interspersed fluid attenuating material.

INVOICE

The right cranial ramus of the pubic bone presents with a transverse fracture and mild caudal deviation of the distal segment.

52230

COMPUTED TOMOGRAPHIC DIAGNOSIS

DATE

6-1-22

- History dog fight and traumatic rupture of the abdominal wall and hernia repair – suspect inguinal hernia – with seroma formation
- Mild emphysema along the left hypaxial musculature along L5 to S1
- Mineralized body distal aspect of left iliopsoas muscle
- Subacute traumatic transverse fracture cranial ramus of pubic bone
- No evidence of persistent defect of the abdominal wall



PATIENT

Maliki Denzel

INTERPRETATION OF THE FINDINGS & FURTHER RECOMMENDATIONS

The CT study presents no evidence of persistent defects of the abdominal wall/herniation of abdominal fat/organs but the large seroma in the inguinal region.

SPECIES

Feline

There is a small mineralized body in the caudal aspect of the left iliopsoas muscle without signs of overt surrounding inflammatory changes and a dislodged osseous fragment is a consideration. However, if signs of inflammation/abscess formation develop, a dental fragment or sequestrum formation warranting surgical management need to be considered.

BREED

DSH

SEX

FE

AGE

20 Weeks

INTERPRETED BY

Sebastian Schaub, DVM
Dr. med. vet. DipECVDI

HOSPITAL NAME

Advanced Veterinary
Imaging

REFERRING VET

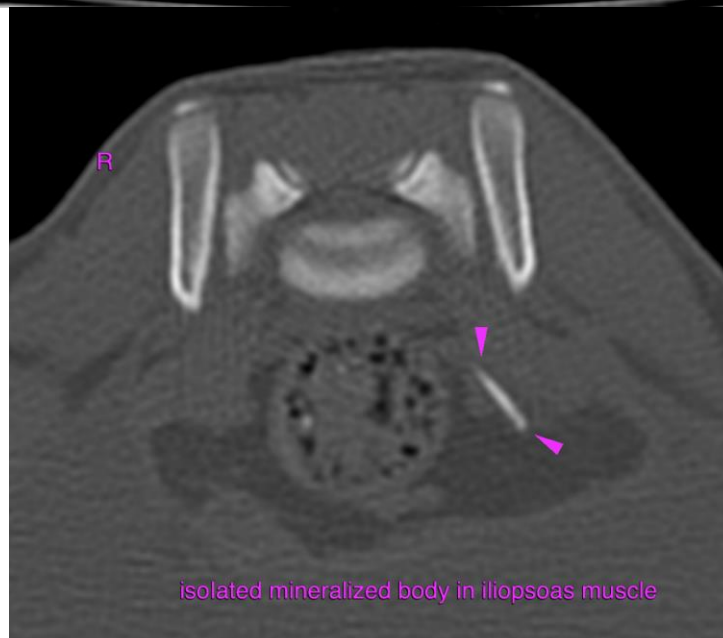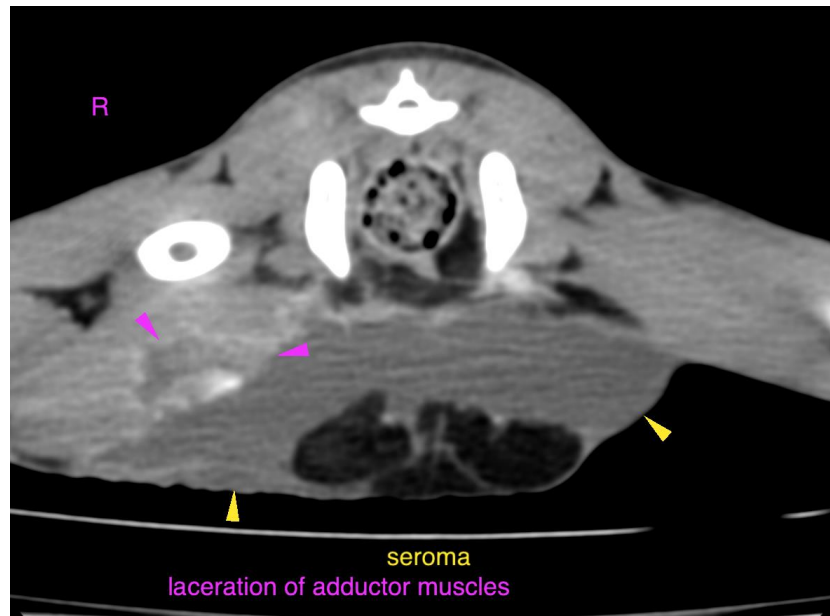
Eamon

INVOICE

52230

DATE

6-1-22





PATIENT

Maliki Denzel

SPECIES

Feline

BREED

DSH

SEX

FE

AGE

20 Weeks

INTERPRETED BY

Sebastian Schaub, DVM
Dr. med. vet. DipECVDI

HOSPITAL NAME

Advanced Veterinary
Imaging

REFERRING VET

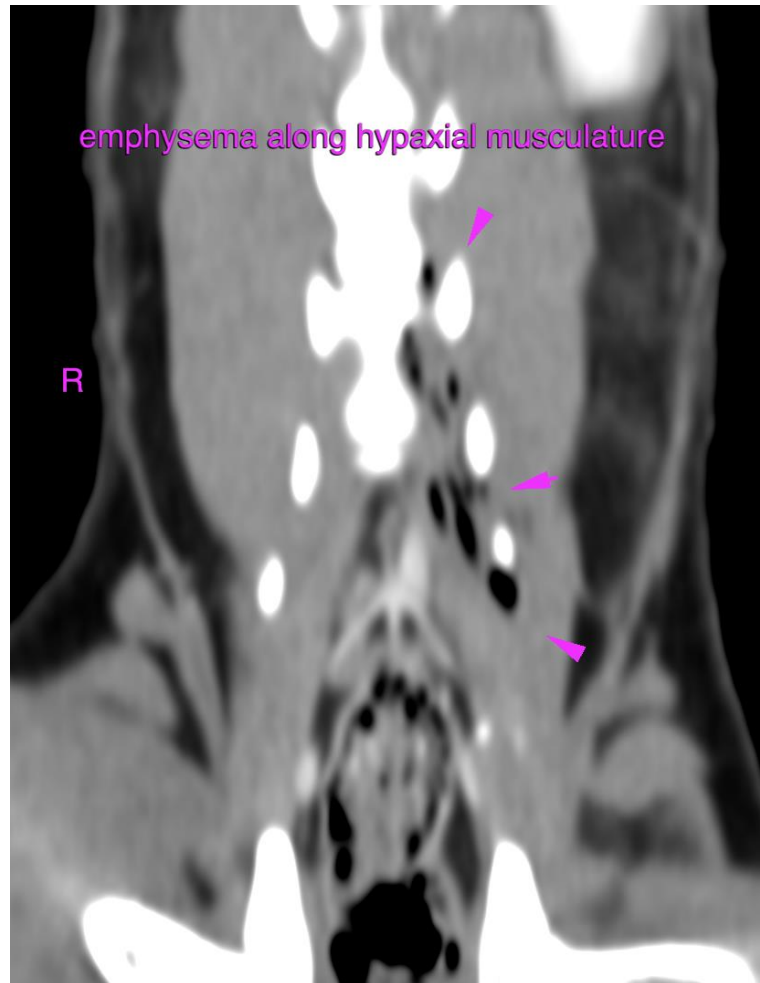Eamon

INVOICE

52230

DATE

6-1-22



The information and recommendations provided are based on the images presented by the referring veterinarian/sonographer. No evaluation can be communicated regarding pathology that was not visible in the image/video clips provided.

Thank you for this referral. If the clinical or image interpretation does not parallel your findings or if I can be of any further assistance please contact me.

Sebastian Schaub, Sebastian Schaub, DVM, Dr. med. vet. DipECVDI
sebast.schaub@gmail.com