

**PATIENT**

Abby Magee

PRESENTING CLINICAL SIGNS

Abby is a 12-year-old spayed poodle mix who has a history of heart murmur 4 out of 6 . She had a history of coughing that got better after giving vetmedin . Abby has started panting over the last few weeks mostly over night.

SPECIES

Canine

RADIOGRAPHIC STUDY OF THE THORAX

Radiographs of the thorax in three imaging planes are provided for review.

BREED

Poodle Mix

RADIOGRAPHIC FINDINGS

The body condition score is 8/9.

The vertebral endplates T9/T10 present mild spondylosis formation.

The subcutaneous fat of the right thoracic wall, level with the 6th right rib presents an ovoid shaped nodular soft tissue lesion is seen.

SEX

Spayed Female

The caudal contour of the cardiac silhouette is steep, and the caudal cardiac waist is lost. The vertebral heart score is 11.4. The pulmonary vasculature is within normal limits.

AGE

13 Years

The cranial mediastinum presents the expected soft tissue opacity. The mediastinal width is less than twice the width of the vertebral column at the same level.

The trachea is normal in diameter and presents the anticipated course. The luminal outline of the trachea is smooth.

INTERPRETED BY

Sebastian Schaub, DVM
Dr. med. vet. DipECVDI

The bronchial tree presents with thin walls and tapers uniformly towards the periphery as expected.

The lung parenchyma presents the expected architecture and opacity; the intrapulmonary vascular branching is seen up to the third order lung vessels.

HOSPITAL NAME

Beaches-Fallingbrook
Veterinary Clinic

The diaphragm is well delineated with even surface and the expected mild cranial bulging of the diaphragmatic cupola.

RADIOGRAPHIC DIAGNOSIS

- Mild to moderate left sided cardiomegaly without signs of decompensation
- Non-specific subcutaneous nodular right thoracic wall
- Spondylosis deformans

REFERRING VET

Dr Sam Shahsavari

INTERPRETATION OF THE FINDINGS & FURTHER RECOMMENDATIONS

The cardiac enlargement is fitting the history of mitral valve disease (ACVIM stage B2). At this point there are no signs for decompensation.

INVOICE

52243

DATE

6-1-22



PATIENT

Abby Magee

SPECIES

Canine

BREED

Poodle Mix

SEX

Spayed Female

AGE

13 Years

INTERPRETED BY

Sebastian Schaub, DVM
Dr. med. vet. DipECVDI

HOSPITAL NAME

Beaches-Fallingbrook
Veterinary Clinic

REFERRING VET

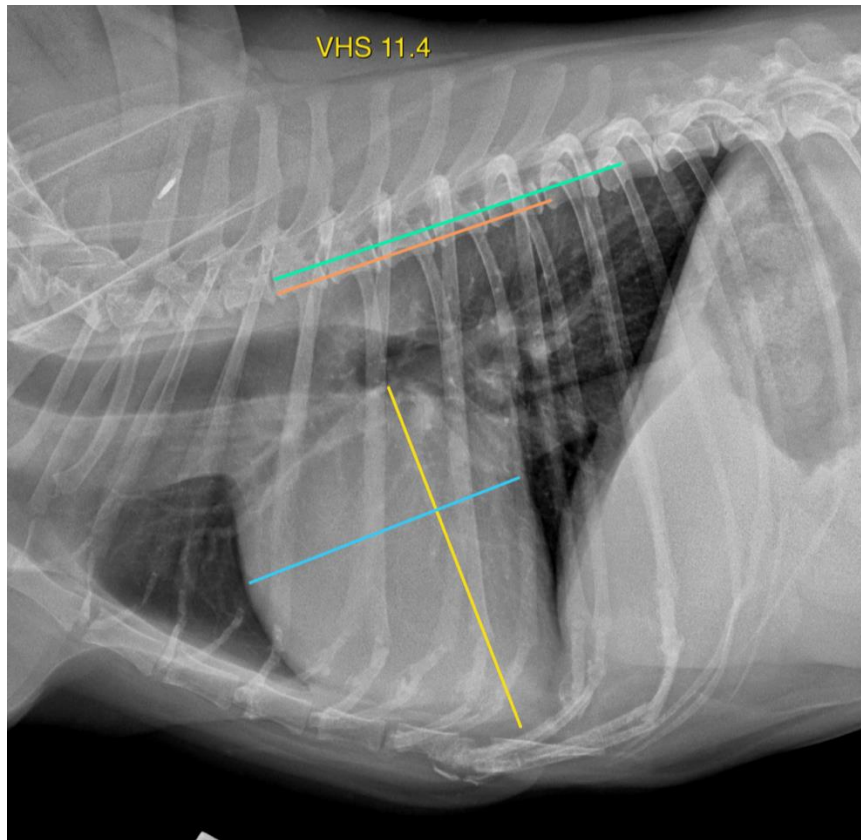
Dr Sam Shahsavari

INVOICE

52243

DATE

6-1-22



The information and recommendations provided are based on the images presented by the referring veterinarian/sonographer. No evaluation can be communicated regarding pathology that was not visible in the image/video clips provided.

Thank you for this referral. If the clinical or image interpretation does not parallel your findings or if I can be of any further assistance please contact me.

Sebastian Schaub, Sebastian Schaub, DVM, Dr. med. vet. DipECVDI
sebast.schaub@gmail.com