



**PATIENT PRESENTING CLINICAL SIGNS**

Abby Brandon Elevated bile acids, concern for liver shunt.  
Abnormal PE/Chem/CBC/UA Results: Bile acids 118.2, post 111.8

**SPECIES COMPUTED TOMOGRAPHY OF THE ABDOMEN**

Canine A high resolution pre- and post-contrast CT study of the abdomen is provided for review.

**COMPUTED TOMOGRAPHIC FINDINGS**

**BREED** The serosal fat presents normal attenuation behavior. There is no evidence of peritoneal effusion or peritonitis.

**Mix** Both kidneys present within normal limits for shape and organ architecture; the renal volume bilaterally is mild to moderately increased. After contrast administration a bilaterally symmetric and uniform nephro- and pyelogram is noted.

**SEX** The adrenal glands are within normal limits for size, shape and organ architecture.

**Intact Female** The spleen presents with normal shape, even surface, uniformly attenuating parenchyma and homogeneous contrast enhancement, unremarkable. At the medial aspect of the cranial extremity of the spleen, an ovoid shaped structure, presenting the same attenuation and contrast enhancement pattern like the spleen is seen – merging with the cranial extremity.

**AGE** 10 Months The hepatic volume is moderately decreased, and the gastric axis is oriented cranially. Originating from the left gastric vein, an anomalous vascular loop is extending cranially beyond the stomach – at the mediadorsal aspect of the fundus of the stomach – coursing between the left hepatic lobes up to the level of the diaphragm. The anomalous vessel has a diameter of 5.2 mm. Level with the diaphragm, the anomalous vascular loop is draining into a moderately dilated phrenic vein. The diameter of the portal vein, cranial to the splenic vein is moderately decreased < left gastric vein.

**INTERPRETED BY**

Sebastian Schaub, DVM  
Dr. med. vet. DipECVDI

The portal vein presents a normal order of its tributary veins and intrahepatic branching. No abnormal vessel is noted inside and outside of the liver parenchyma.

**HOSPITAL NAME**

Mobile Pet Imaging

The pancreas is evenly contoured, the pancreatic parenchyma is homogeneous and presents uniform contrast enhancement.

**REFERRING VET**

Meaux

The position, delineation, wall and content of the gastrointestinal tract are considered within normal limits throughout.

The bony and surrounding soft tissue structures reveal no abnormalities.

**COMPUTED TOMOGRAPHIC DIAGNOSIS**

- INVOICE**
- Single congenital extrahepatic portosystemic shunt, left gastric vein to phrenic vein (portophrenic shunt)
  - Secondary microhepatica & renomegaly
  - Splenunculus versus normal anatomical variant of splenic head with small ovoid shaped protrusion

**DATE**

6-1-22



**PATIENT INTERPRETATION OF THE FINDINGS & FURTHER RECOMMENDATIONS**

**Abby Brandon** The findings are consistent with a congenital single extrahepatic portosystemic shunt, originating from the left gastric vein and draining to a left phrenic vein (portophrenic shunt).

**SPECIES** Surgical intervention by a slow progressive closure technique (ameroid constrictor, cellophane banding) is the therapy of choice. Empirical treatment until surgery along with feeding of a hepatic diet is recommended.

Canine

**BREED**

Mix

**SEX**

Intact Female

**AGE**

10 Months

**INTERPRETED BY**

Sebastian Schaub, DVM  
Dr. med. vet. DipECVDI

**HOSPITAL NAME**

Mobile Pet Imaging

**REFERRING VET**

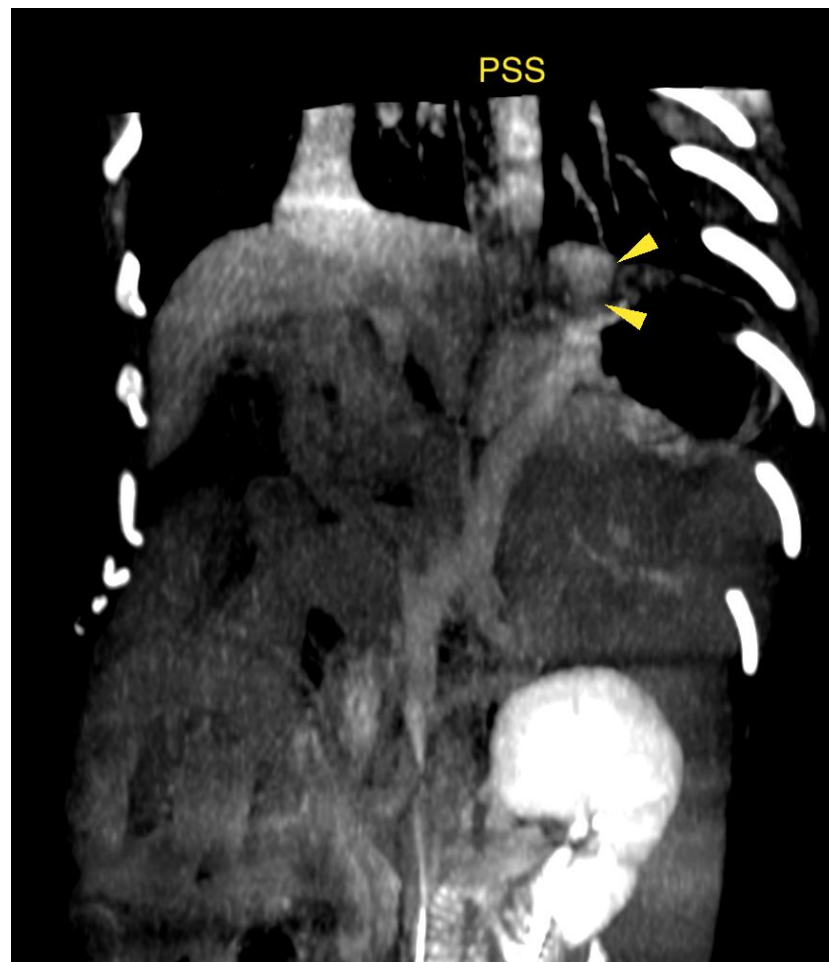
Meaux

**INVOICE**

52238

**DATE**

6-1-22





**PATIENT**

Abby Brandon

**SPECIES**

Canine

**BREED**

Mix

**SEX**

Intact Female

**AGE**

10 Months

**INTERPRETED BY**

Sebastian Schaub, DVM  
Dr. med. vet. DipECVDI

**HOSPITAL NAME**

Mobile Pet Imaging

**REFERRING VET**

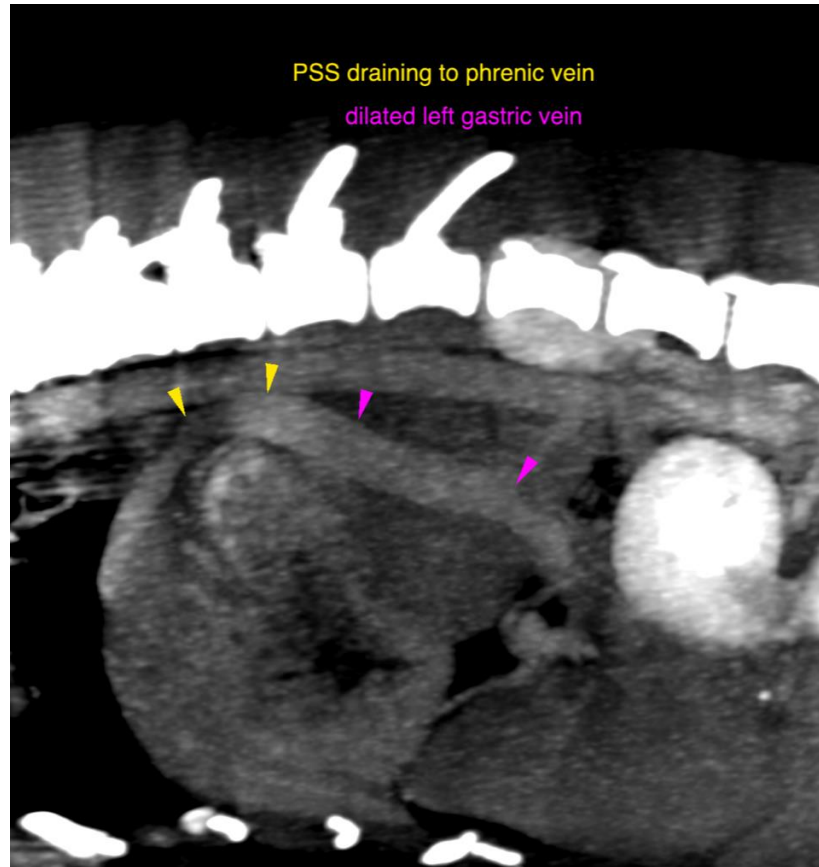
Meaux

**INVOICE**

52238

**DATE**

6-1-22



The information and recommendations provided are based on the images presented by the referring veterinarian/sonographer. No evaluation can be communicated regarding pathology that was not visible in the image/video clips provided.

Thank you for this referral. If the clinical or image interpretation does not parallel your findings or if I can be of any further assistance please contact me.

**Sebastian Schaub**, Sebastian Schaub, DVM, Dr. med. vet. DipECVDI  
sebast.schaub@gmail.com