



**PATIENT PRESENTING CLINICAL SIGNS**

Helen #641E Smotherman-Williams  
Owners have noticed dry coughing fits that started 2 weeks ago. Coughing fits last for about a minute and occur about 6-10 times daily according to owner. Patient has a history of seizures that are controlled on phenobarbital and keppra. Patient was on clavamox for a UTI when coughing started. Abnormal PE/Chem/CBC/UA Results: Long term obesity- working on weight loss

**SPECIES RADIOGRAPHIC STUDY OF THE THORAX**

Feline Radiographs of the thorax in three imaging planes are provided for review.

**RADIOGRAPHIC FINDINGS**

**BREED** The body condition score is 8/9.

DSH The surrounding bony structures are within normal limits.

The extrathoracic soft tissues present homogeneous without abnormalities.

**SEX** The heart is of normal size and shape, there is no evidence of cardiac chamber or vascular enlargement. The pulmonary vasculature is within normal limits.

FS The trachea is normal in diameter and presents the anticipated course. The luminal outline of the trachea is smooth.

**AGE** Equivocal mild increased visibility of the bronchial walls of the right lung lobes is appreciated.

8 Years, 2 Months The lung parenchyma is hypoinflated in the lateral projections, accentuating a generalized ground glass opacity – not appreciated in the VD view.

**INTERPRETED BY** The diaphragm is well delineated with even surface and the expected mild cranial bulging of the diaphragmatic cupola.

Sebastian Schaub, DVM  
Dr. med. vet. DipECVDI

**RADIOGRAPHIC DIAGNOSIS**

- Obesity
- Equivocal mild bronchial pattern right lung lobes

**HOSPITAL NAME**

Gentle Doctor Animal  
Hospitals

**INTERPRETATION OF THE FINDINGS & FURTHER RECOMMENDATIONS**

**REFERRING VET** The radiographic study presents without specific abnormalities. The diagnosis of bronchial pattern is not definitive, however in combination with the coughing fits bronchitis would be a plausible diagnosis – either primary allergic or infectious (viral, bacterial, parasitic) in origin.

Dr. Rotthaus

**INVOICE**

58215

**DATE**

5-9-23



**PATIENT**

Helen #641E  
Smotherman-  
Williams

**SPECIES**

Feline

**BREED**

DSH

**SEX**

FS

**AGE**

8 Years, 2 Months

**INTERPRETED BY**

Sebastian Schaub, DVM  
Dr. med. vet. DipECVDI

**HOSPITAL NAME**

Gentle Doctor Animal  
Hospitals

**REFERRING VET**

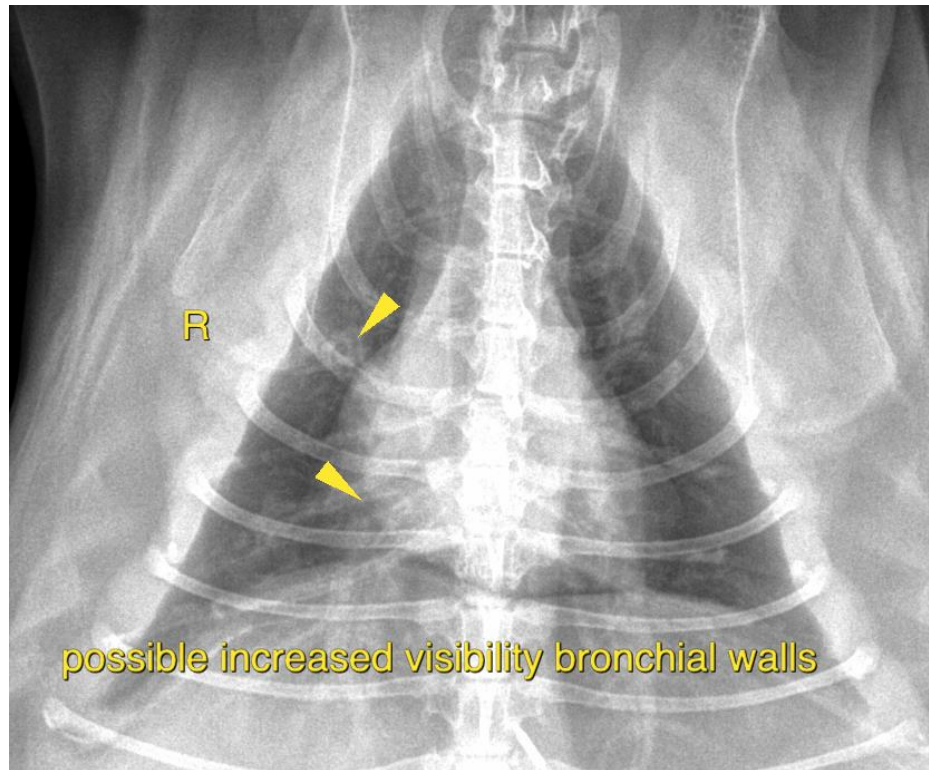
Dr. Rotthaus

**INVOICE**

58215

**DATE**

5-9-23



The information and recommendations provided are based on the images presented by the referring veterinarian/sonographer. No evaluation can be communicated regarding pathology that was not visible in the image/video clips provided.

Thank you for this referral. If the clinical or image interpretation does not parallel your findings or if I can be of any further assistance please contact me.

**Sebastian Schaub**, Sebastian Schaub, DVM, Dr. med. vet. DipECVDI  
sebast.schaub@gmail.com