



PATIENT

Sugar Shao

PRESENTING CLINICAL SIGNS

Pt presented for COHAT.

SPECIES

Canine

COMPUTED TOMOGRAPHY OF THE SKULL

A high resolution plain CT study of the skull is provided for review.

BREED

Mixed

COMPUTED TOMOGRAPHIC FINDINGS

All teeth but triadan 104, 110, 204, 210, 304, 307-310 and 404 are absent. Triadan 310 presents a moderate widened periodontal space and the distal root presents with a small resorptive lesion. The remaining teeth present a mild horizontal bone loss.

SEX

MN

Mild atrophy of the nasal conchal structures of the left nasal cavity is appreciated.

Both temporomandibular joints present congruent joint spaces with even subchondral bone surfaces and are considered within normal limits.

Both tympanic bullae are aerated, the mucosal lining is not seen, the bony wall is smooth and thin. The external ear canals are within normal limits.

AGE

9 Years

COMPUTED TOMOGRAPHIC DIAGNOSIS

- Moderate periodontal disease 310
- Generalized mild periodontal disease of the remaining teeth
- Left sided nasal conchal atrophy
- Multiple absent teeth

INTERPRETED BY

Sebastian Schaub, DVM
Dr. med. vet. DipECVDI

INTERPRETATION OF THE FINDINGS & FURTHER RECOMMENDATIONS

Triadan 310 presents with advanced periodontal disease, the remainder of the dentition show evidence of mild periodontal disease. A complete dental workup has already been performed.

The conchal atrophy is likely a sequela to preceding rhinitis, at this point there is no evidence of active rhinitis.

HOSPITAL NAME

South Bay Animal
Hospital & Pet Resort

REFERRING VET

Dr. Rupashree Rao

INVOICE

52013

DATE

5-9-22



PATIENT

Sugar Shao

SPECIES

Canine

BREED

Mixed

SEX

MN

AGE

9 Years

INTERPRETED BY

Sebastian Schaub, DVM
Dr. med. vet. DipECVDI

HOSPITAL NAME

South Bay Animal
Hospital & Pet Resort

REFERRING VET

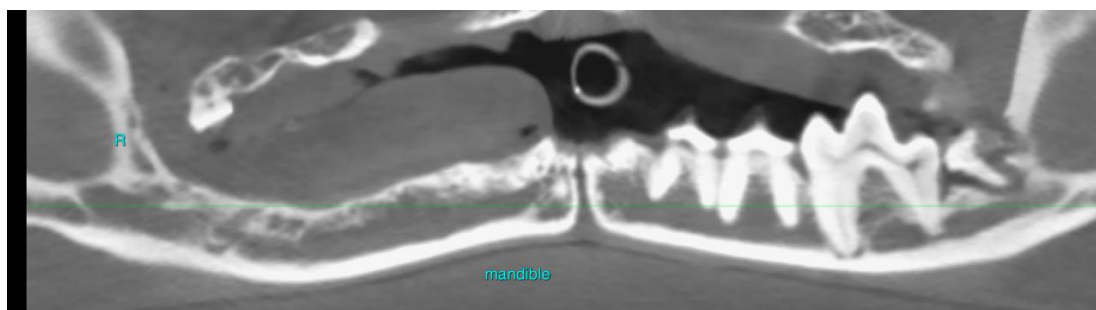
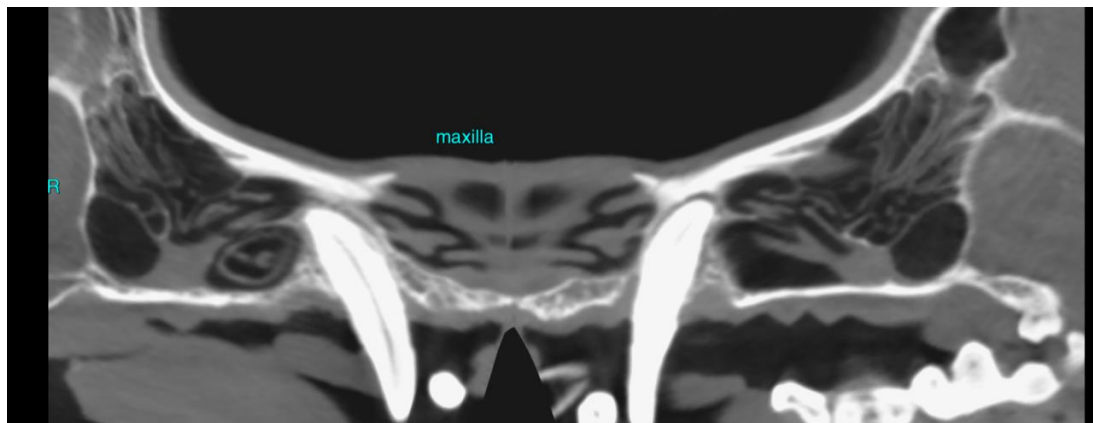
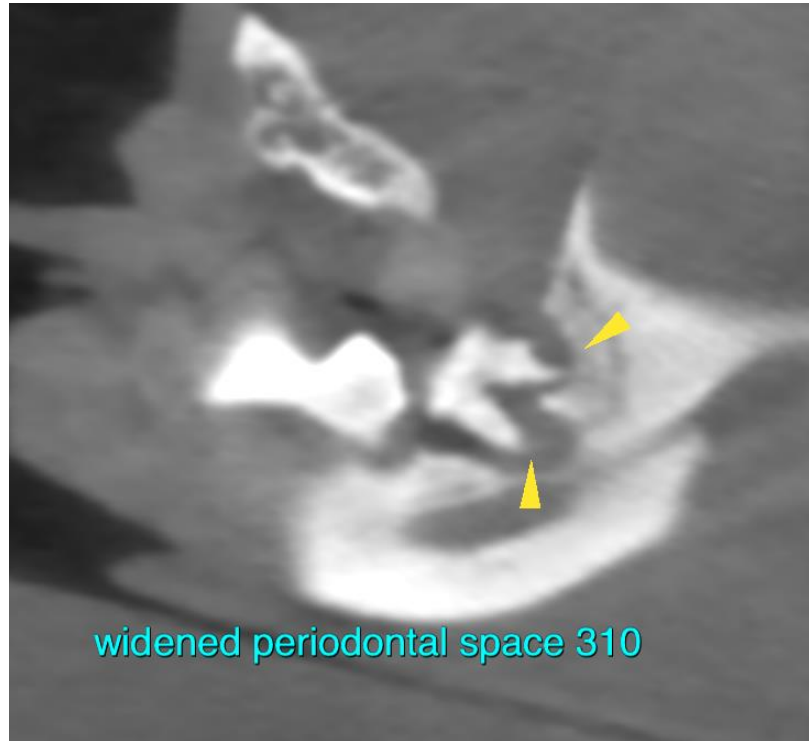
Dr. Rupashree Rao

INVOICE

52013

DATE

5-9-22





PATIENT

Sugar Shao

SPECIES

Canine

BREED

Mixed

SEX

MN

AGE

9 Years

INTERPRETED BY

Sebastian Schaub, DVM
Dr. med. vet. DipECVDI

HOSPITAL NAME

South Bay Animal
Hospital & Pet Resort

REFERRING VET

Dr. Rupashree Rao

INVOICE

52013

DATE

5-9-22

The information and recommendations provided are based on the images presented by the referring veterinarian/sonographer. No evaluation can be communicated regarding pathology that was not visible in the image/video clips provided.

Thank you for this referral. If the clinical or image interpretation does not parallel your findings or if I can be of any further assistance please contact me.

Sebastian Schaub, Sebastian Schaub, DVM, Dr. med. vet. DipECVDI
sebast.schaub@gmail.com