



PATIENT

Rizzo Venegas

PRESENTING CLINICAL SIGNS

Seizures of unknown origin

SPECIES

Canine

COMPUTED TOMOGRAPHY OF THE ABDOMEN

A high resolution pre- and post-contrast CT study of the cranial abdomen is provided for review.

BREED

French Bulldog

COMPUTED TOMOGRAPHIC FINDINGS

The serosal fat presents normal attenuation behavior. There is no evidence of peritoneal effusion or peritonitis.

SEX

Intact Female

Both kidneys present within normal limits for size, shape and organ architecture. After contrast administration a bilaterally symmetric and uniform nephro- and pyelogram is noted.

The adrenal glands are within normal limits for size, shape and organ architecture.

Both liver and spleen present with normal shape, even surface, uniformly attenuating parenchyma and homogeneous contrast enhancement, unremarkable.

The portal vein presents a normal order of its tributary veins and intrahepatic branching. No abnormal vessel is noted inside and outside of the liver parenchyma.

AGE

17 Weeks

A separate left & right caudal vena cava of the pictured pre-renal segment is appreciated.

The pancreas is evenly contoured, the pancreatic parenchyma is homogeneous and presents uniform contrast enhancement.

The position, delineation, wall and content of the gastrointestinal tract are considered within normal limits throughout.

The bony and surrounding soft tissue structures reveal no abnormalities.

INTERPRETED BY

Sebastian Schaub, DVM
Dr. med. vet. DipECVDI

COMPUTED TOMOGRAPHIC DIAGNOSIS

- No evidence of portosystemic shunting, neither intra- nor extrahepatic
- Incidental double caudal vena cava

HOSPITAL NAME

Queen Creek
Veterinary Clinic

INTERPRETATION OF THE FINDINGS & FURTHER RECOMMENDATIONS

No macroscopic vascular bypass of the liver was noted in the pre- and post- contrast studies of the abdomen. If the clinical signs are consistent with insufficiency of the liver primary non-cirrhotic portal hypertension (microvascular dysplasia) or other diffuse parenchymal liver disease would still be a potential and should be ruled out by means of ultrasound guided or surgical liver biopsy.

REFERRING VET

Dr. Kurth

INVOICE

52020

DATE

5-9-22



PATIENT

Rizzo Venegas

SPECIES

Canine

BREED

French Bulldog

SEX

Intact Female

AGE

17 Weeks

INTERPRETED BY

Sebastian Schaub, DVM
Dr. med. vet. DipECVDI

HOSPITAL NAME

Queen Creek
Veterinary Clinic

REFERRING VET

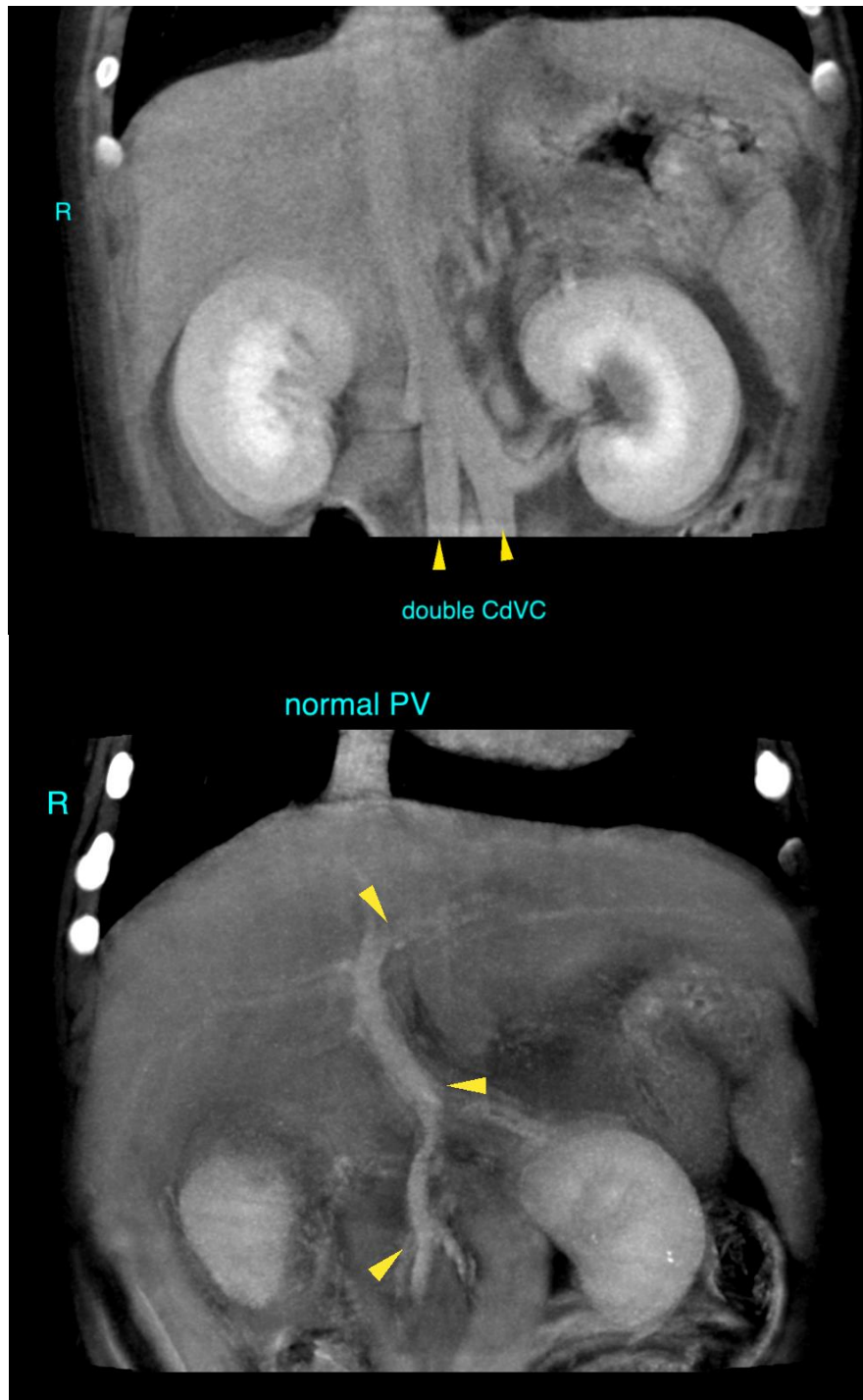
Dr. Kurth

INVOICE

52020

DATE

5-9-22





PATIENT

Rizzo Venegas

SPECIES

Canine

The information and recommendations provided are based on the images presented by the referring veterinarian/sonographer. No evaluation can be communicated regarding pathology that was not visible in the image/video clips provided.

BREED

French Bulldog

Thank you for this referral. If the clinical or image interpretation does not parallel your findings or if I can be of any further assistance please contact me.

Sebastian Schaub, Sebastian Schaub, DVM, Dr. med. vet. DipECVDI
sebast.schaub@gmail.com

SEX

Intact Female

AGE

17 Weeks

INTERPRETED BY

Sebastian Schaub, DVM
Dr. med. vet. DipECVDI

HOSPITAL NAME

Queen Creek
Veterinary Clinic

REFERRING VET

Dr. Kurth

INVOICE

52020

DATE

5-9-22