



PATIENT

Zoey Iurato

SPECIES

Canine

BREED

Shih Poo

SEX

Spayed Female

AGE

14 Years

WEIGHT

14 lbs

INTERPRETED BY

Sebastian Schaub, DVM
Dr. med. vet. DipECVDI

IMAGING PERFORMED BY

Hamburg Veterinary
Clinic

HOSPITAL NAME

Hamburg Veterinary
Clinic

REFERRING VET

Dr. DenHever

INVOICE

16056

DATE

05/08/26

PRESENTING CLINICAL SIGNS

Dental performed 1 week ago, on Clavamox and Baytril for pneumonia, tachypneic, anorexic

RADIOGRAPHIC STUDY OF THE THORAX

Radiographs of the thorax in two imaging planes are provided for review.

RADIOGRAPHIC FINDINGS

The surrounding bony structures are within normal limits.

The extrathoracic soft tissues present homogeneous without abnormalities.

The heart is of normal size and shape, there is no evidence of cardiac chamber or vascular enlargement.

The cranial mediastinum presents the expected soft tissue opacity. The mediastinal width is less than twice the width of the vertebral column at the same level.

The trachea is normal in diameter and presents the anticipated course. The luminal outline of the trachea is smooth.

The lung parenchyma presents a generalized – mild patchy – unstructured reticular pattern, effacing the pulmonary vessels.

In the VD view, thin pleural fissure lines are appreciated.

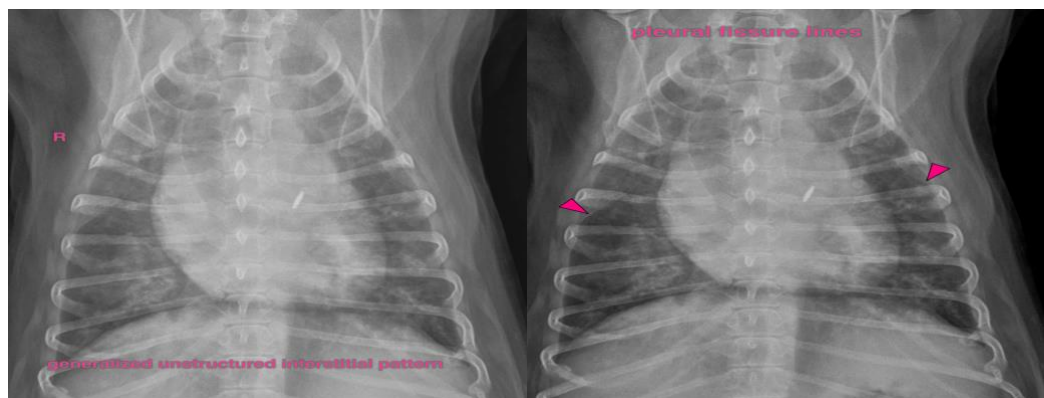
The diaphragm is well delineated with even surface and the expected mild cranial bulging of the diaphragmatic cupola.

RADIOGRAPHIC DIAGNOSIS

- Generalized unstructured interstitial pattern
- Possible mild pleural effusion

INTERPRETATION OF THE FINDINGS & FURTHER RECOMMENDATIONS

The unstructured interstitial pattern is not specific, however in case of an acute onset of clinical signs the odds for infectious pneumonia are high. Differentials would include fibrosis, systemic disease (e.g. pancreatitis, IMHA, renal disease), early stage of pulmonary hemorrhage or less likely here neoplasia. Follow up radiographs can be performed to screen if the lung pattern does change under empirical therapy.





PATIENT

Zoey Iurato

SPECIES

Canine

BREED

Shih Poo

SEX

Spayed Female

AGE

14 Years

WEIGHT

14 lbs

INTERPRETED BY

Sebastian Schaub, DVM
Dr. med. vet. DipECVDI

IMAGING PERFORMED BY

Hamburg Veterinary
Clinic

HOSPITAL NAME

Hamburg Veterinary
Clinic

REFERRING VET

Dr. DenHever

INVOICE

16056

DATE

05/08/26

The information and recommendations provided are based on the images presented by the referring veterinarian/sonographer. No evaluation can be communicated regarding pathology that was not visible in the image/video clips provided.

Thank you for this referral. If the clinical or image interpretation does not parallel your findings or if I can be of any further assistance please contact me.

Sebastian Schaub, DVM, Dr. med. vet. DipECVDI
info@sonopath.com