



PATIENT

Chico Miranda

SPECIES

Canine

BREED

Bull Terrier

SEX

Male

AGE

4 Years

WEIGHT

57 lbs

INTERPRETED BY

Sebastian Schaub, DVM
Dr. med. vet. DipECVDI

IMAGING PERFORMED BY

Carmen

HOSPITAL NAME

Animal Clinic of
Queens

REFERRING VET

Dr. Mucera

INVOICE

16055

DATE

05/08/26

PRESENTING CLINICAL SIGNS

Pt has been limping on the left hind leg for >2weeks. Painful on extension. Minimal improvement on anti-inflammatories.

RADIOGRAPHIC STUDY OF THE PELVIS AND STIFLE JOINTS

A complete set of radiographs of the pelvis and stifle joints is provided for review.

RADIOGRAPHIC FINDINGS

The osseous structures of the pelvis are within normal limits. Both coxofemoral joints present smooth osseous margins and congruent joint spaces. At the caudal aspect of the ischial tuberosity, an irregular roundish mineralization is visible.

The volume of the soft tissue shadow of the musculature of the left hind limb is mildly decreased.

The periarticular bones of the left stifle joint present moderate osteophyte new bone formation. The left stifle joint presents a moderate intracapsular soft tissue swelling, effacing the infrapatellar fat pad cranially and distorting the fascial plane caudally.

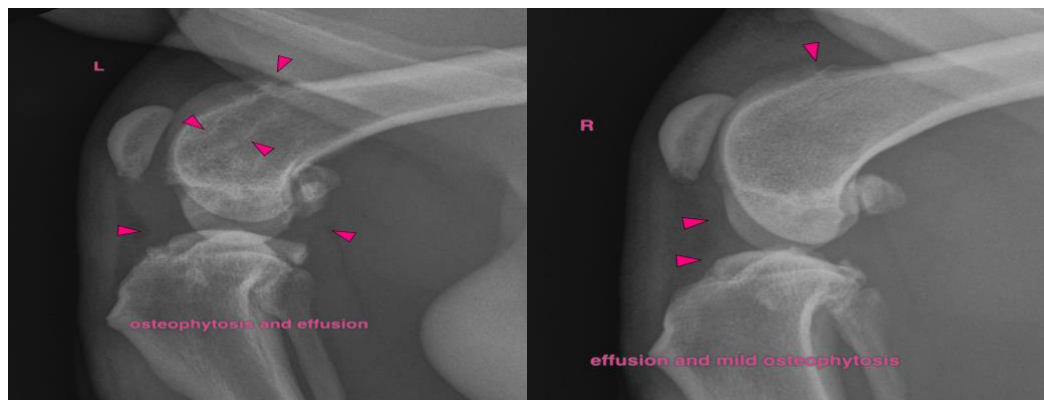
The periarticular bones of the right stifle joint present mild osteophyte new bone formation. The right stifle joint presents a mild intracapsular soft tissue swelling – partially effacing the infrapatellar fat pad cranially.

RADIOGRAPHIC DIAGNOSIS

- Moderate osteoarthritis left stifle joint
- Mild osteoarthritis right stifle joint
- Articular swelling both stifle joints, L>>R
- Metaplasia caudal to left ischial tuberosity
- Normal coxofemoral joints

INTERPRETATION OF THE FINDINGS & FURTHER RECOMMENDATIONS

The degenerative joint disease of the stifle joints is commonly a sequela to pathology of the cranial cruciate ligament ± meniscal pathology. A positive drawer sign or tibial compression test under general anesthesia will support the diagnosis – partial rupture of the cranial cruciate ligament and potential thickening of the synovial capsule can result in only mild instability.





PATIENT

Chico Miranda

SPECIES

Canine

BREED

Bull Terrier

SEX

Male

AGE

4 Years

WEIGHT

57 lbs

INTERPRETED BY

Sebastian Schaub, DVM
Dr. med. vet. DipECVDI

IMAGING PERFORMED BY

Carmen

HOSPITAL NAME

Animal Clinic of
Queens

REFERRING VET

Dr. Mucera

INVOICE

16055

DATE

05/08/26

The information and recommendations provided are based on the images presented by the referring veterinarian/sonographer. No evaluation can be communicated regarding pathology that was not visible in the image/video clips provided.

Thank you for this referral. If the clinical or image interpretation does not parallel your findings or if I can be of any further assistance please contact me.

Sebastian Schaub, DVM, Dr. med. vet. DipECVDI
info@sonopath.com