



PATIENT PRESENTING CLINICAL SIGNS

Scooby Cox P was seen on 5/5 for vestibular disease; p is not improving and is worsening, now won't eat all, will barely move. Meds (meclizine, cerenia, and baytril) not helping. O elected to have CT On 5/5 P was seen after being attacked by dog 1 month prior. Been fine since then until now. Been not acting right for 1 week prior. Had an ear infection a few years ago. Off balance yesterday and today, falling over. Leaning to the right. Yelping upon getting up and turning head. shaking when laying down. No vomiting or diarrhea. Seems to have a hard time eating; drinking normal. May be nauseous. Normal U/D. Last full meal was yesterday. O thinks felt something on R side of neck. P placed on meclizine, cerenia, and baytril.

SPECIES Canine
BREED Abnormal PE/Chem/CBC/UA Results: 5-7% dehydrated Ambulatory x4; weak on R; leaning and circling to R; NSF on ROM or palpation of neck CN intact, head tilt and circling to R; ataxic; normal deep pain and CPs x 4 BW obtained - Glob 4, Glu 130, ALP 444. Overall NSF.
 Boxer Mix

COMPUTED TOMOGRAPHY OF THE SKULL & NECK

SEX A high resolution pre- and post-contrast CT study of the skull is provided for review.

MN COMPUTED TOMOGRAPHIC FINDINGS

The pictured parts of the dentition are complete and unremarkable in all jaw quadrants.

AGE Both temporomandibular joints present congruent joint spaces with even subchondral bone surfaces and are considered within normal limits.

8 Years Both tympanic bullae are aerated, the mucosal lining is not seen, the bony wall is smooth and thin. The external ear canals are within normal limits.

INTERPRETED BY

Sebastian Schaub, DVM
 Dr. med. vet. DipECVDI

Along the dorsal and lateral aspect of the calvarium, R>L, involving the parietal bone bilaterally, right temporal bone and extending caudally along the occipital bone, an amorphous mineralizing mass is bulging from the surface of the calvarium dorsally and caudally. The amorphous mineralization is embedded within a soft tissue attenuating and heterogeneous contrast enhancing matrix – presenting feathered margins to the surrounding temporal musculature. The osseous lining presents multifocal moth eaten osteolytic lesions and amorphous mineralization are appreciated protruding into the cranial fossa and the tentorium osseum cerebelli – presenting a mass effect on the cerebellum and occipital lobe of the telencephalon bilaterally. In the caudal aspect the mass is overlapping the cranial part of the spinous process of C2.

HOSPITAL NAME

Animal Emergency Hospital Volusia

REFERRING VET

Dr. Bogosian

The submandibular and medial retropharyngeal lymph nodes are small and elongated with a normal short-to-long-axis-ratio is < 0.5, the attenuation and contrast enhancement pattern is uniform.

COMPUTED TOMOGRAPHIC DIAGNOSIS

- Polyostotic aggressive predominant osteoproliferative mass originating from the calvarium with invasion of the cranial fossa

INVOICE

58165

INTERPRETATION OF THE FINDINGS & FURTHER RECOMMENDATIONS

The findings are consistent with neoplastic transformation of major parts of the calvarium with evidence of invasion of the cranial fossa. Differentials can include osteosarcoma, osteochondrosarcoma, chondrosarcoma, round cell tumor. FNA sampling of the mass might be performed for further definition. The prognosis is considered poor to infaust.

DATE

5-8-23



PATIENT

Scooby Cox

SPECIES

Canine

BREED

Boxer Mix

SEX

MN

AGE

8 Years

INTERPRETED BY

Sebastian Schaub, DVM
Dr. med. vet. DipECVDI

HOSPITAL NAME

Animal Emergency
Hospital Volusia

REFERRING VET

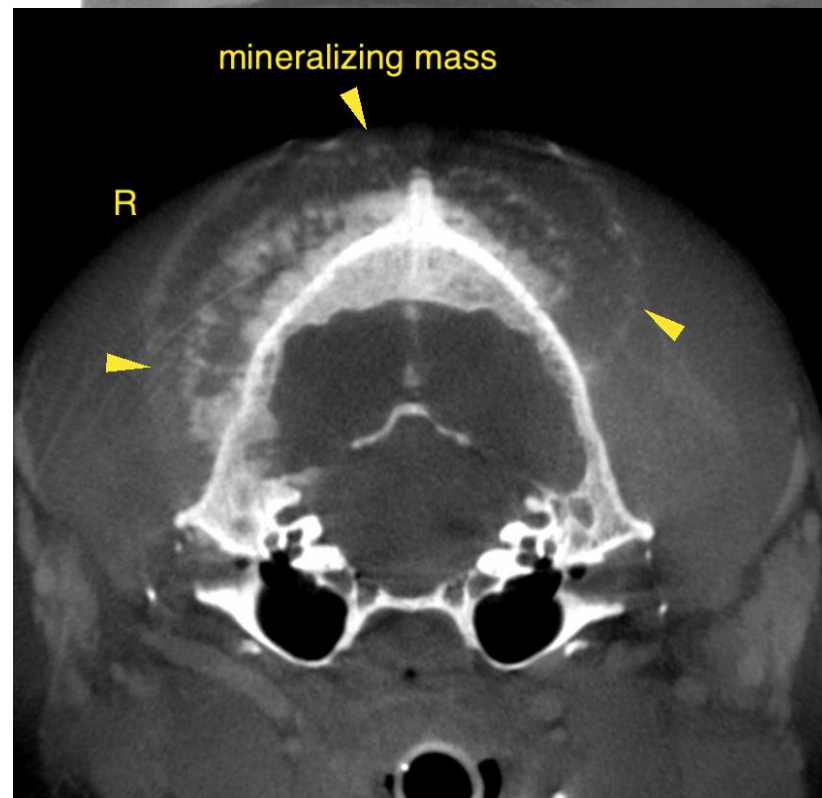
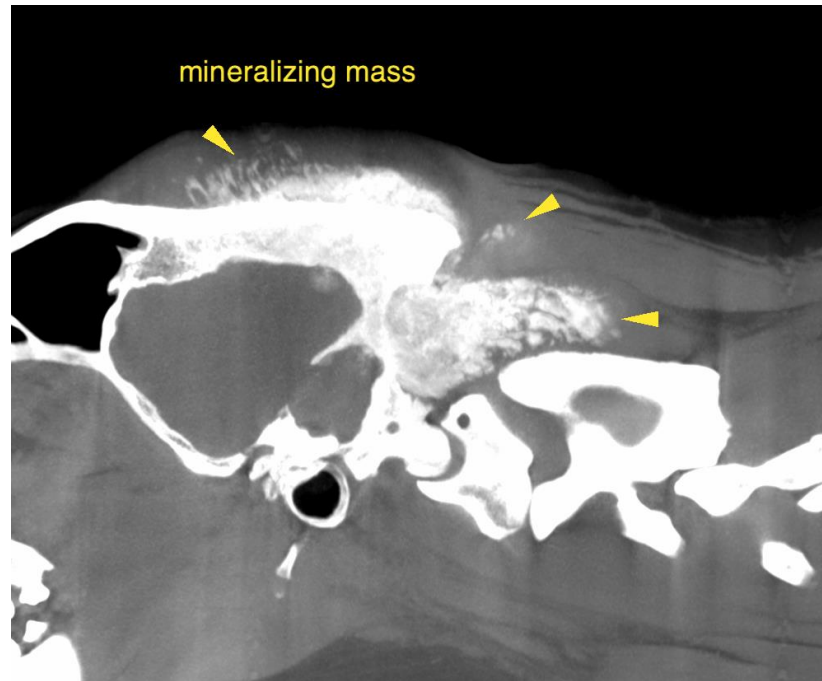
Dr. Bogosian

INVOICE

58165

DATE

5-8-23





PATIENT

Scooby Cox

SPECIES

Canine

BREED

Boxer Mix

SEX

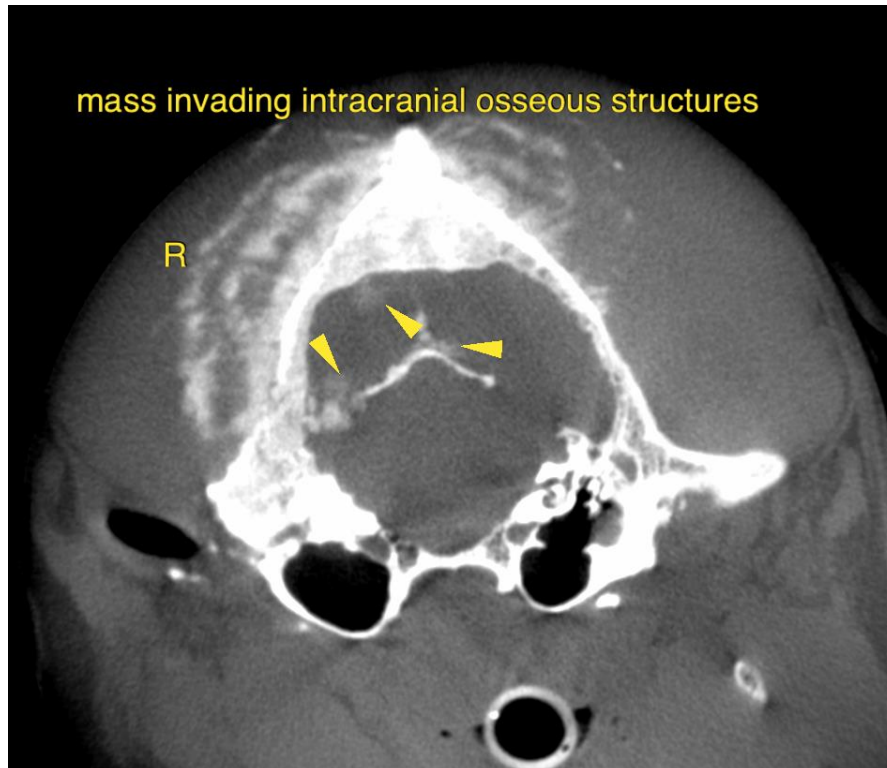
MN

AGE

8 Years

INTERPRETED BY

Sebastian Schaub, DVM
Dr. med. vet. DipECVDI



HOSPITAL NAME

Animal Emergency
Hospital Volusia

REFERRING VET

Dr. Bogosian

INVOICE

58165

DATE

5-8-23

The information and recommendations provided are based on the images presented by the referring veterinarian/sonographer. No evaluation can be communicated regarding pathology that was not visible in the image/video clips provided.

Thank you for this referral. If the clinical or image interpretation does not parallel your findings or if I can be of any further assistance please contact me.

Sebastian Schaub, Sebastian Schaub, DVM, Dr. med. vet. DipECVDI
sebast.schaub@gmail.com