



**PATIENT**

Yofi Levkovsky

**PRESENTING CLINICAL SIGNS**

P was presented for acute cervical pain. No history of trauma. Per O P is sedentary. Abnormal PE/Chem/CBC/UA Results: Pain on cervical flexion to the right. Slightly delayed CPs along the thoracic limbs. No additional diagnostics performed.

**SPECIES**

K9

**RADIOGRAPHIC STUDY OF THE CERVICAL SPINE**

Radiographs of the cervical spine in two imaging planes are provided for review.

**BREED**

Chihuahua

**RADIOGRAPHIC FINDINGS**

The front limbs are superimposed on the caudal cervical spine.

The intervertebral disc space C4/C5 appears narrowed, but there is oblique projection of the respective intervertebral disc space.

**SEX**

Male Neutered

The vertebral endplates C6/C7 present moderate spondylosis formation, the respective intervertebral disc space is collapsed.

The remainder of the osseous and surrounding soft tissue structures are within normal limits.

**AGE**

15 Years, 7 Months

Medial luxation of the humeral heads bilaterally is appreciated.

**INTERPRETED BY**

Sebastian Schaub, DVM  
Dr. med. vet. DipECVDI

**RADIOGRAPHIC DIAGNOSIS**

- Possible discopathy C4/C5
- Chronic discopathy C6/C7
- Spondylosis deformans C6/C7
- Medial luxation of the humeral heads bilaterally

**INTERPRETATION OF THE FINDINGS & FURTHER RECOMMENDATIONS**

**HOSPITAL NAME**

DTLAvets

The discopathy C6/C7 and possible discopathy C4/C5 might be associated with compressive myelopathy and can be a source for pain. If clinical signs are refractory to empirical management, recommend CT or MRI study of the cervical spine.

**REFERRING VET**

Dr. Endo

The bilateral medial luxation of the shoulder joints is considered as an incidental finding, due to the lack of clinical signs – is likely a chronic finding.

**INVOICE**

51963

**DATE**

5-7-22



**PATIENT**

Yofi Levkovsky

**SPECIES**

K9

**BREED**

Chihuahua

**SEX**

Male Neutered

**AGE**

15 Years, 7 Months

**INTERPRETED BY**

Sebastian Schaub, DVM  
Dr. med. vet. DipECVDI

**HOSPITAL NAME**

DTLAvets

**REFERRING VET**

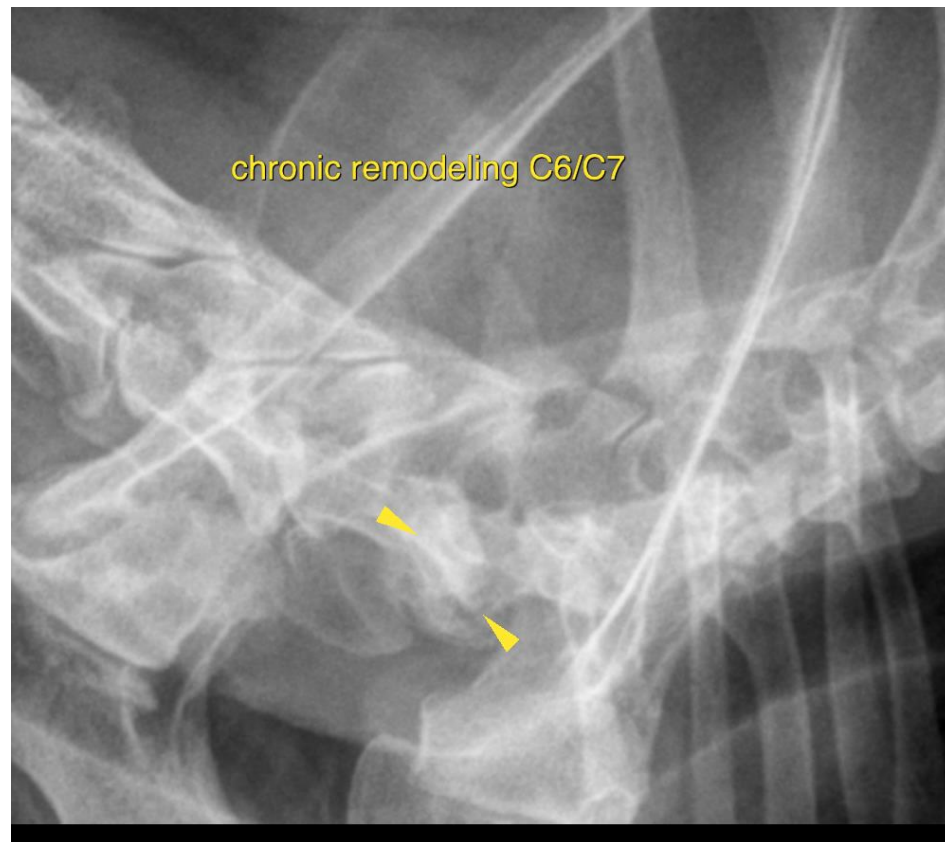
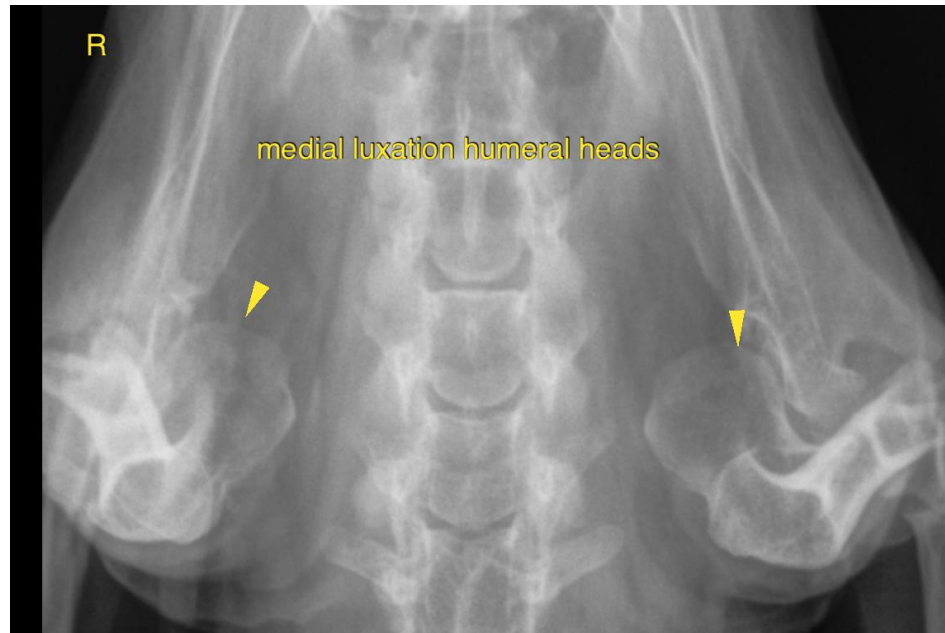
Dr. Endo

**INVOICE**

51963

**DATE**

5-7-22





**PATIENT**

Yofi Levkovsky

The information and recommendations provided are based on the images presented by the referring veterinarian/sonographer. No evaluation can be communicated regarding pathology that was not visible in the image/video clips provided.

**SPECIES**

K9

Thank you for this referral. If the clinical or image interpretation does not parallel your findings or if I can be of any further assistance please contact me.

**Sebastian Schaub**, Sebastian Schaub, DVM, Dr. med. vet. DipECVDI  
sebast.schaub@gmail.com

**BREED**

Chihuahua

**SEX**

Male Neutered

**AGE**

15 Years, 7 Months

**INTERPRETED BY**

Sebastian Schaub, DVM  
Dr. med. vet. DipECVDI

**HOSPITAL NAME**

DTLAvets

**REFERRING VET**

Dr. Endo

**INVOICE**

51963

**DATE**

5-7-22