



PATIENT

Shadow Vargas

PRESENTING CLINICAL SIGNS

presented for tooth root abscess

SPECIES

Canine

COMPUTED TOMOGRAPHY OF THE SKULL

A high resolution plain CT study of the skull is provided for review.

BREED

Mixed Breed

COMPUTED TOMOGRAPHIC FINDINGS

The tooth elements 101, 102, 110, 201, 202, 210, 301, 305, 401 and 405 are absent. All remaining maxillary and mandibular premolar and molar teeth present a moderate to marked widening of the periodontal space. A significant amount of mineralized material is attached to the crowns of the premolar and molar teeth. The mesial palatine root of triadan 208 is perforating the left nasal cavity.

SEX

Male Neutered

In the left nasal cavity, moderate destruction of the nasal conchal structures is appreciated.

Both temporomandibular joints present congruent joint spaces with even subchondral bone surfaces and are considered within normal limits.

AGE

11 Years

Both tympanic bullae are aerated, the mucosal lining is not seen, the bony wall is smooth and thin. The external ear canals are within normal limits.

INTERPRETED BY

Sebastian Schaub, DVM
Dr. med. vet. DipECVDI

COMPUTED TOMOGRAPHIC DIAGNOSIS

- Advanced periodontal disease all premolar and molar teeth with oronasal fistula formation 208
- Left sided odontogenic destructive rhinitis
- Dental tartar

HOSPITAL NAME

South Bay Animal
Hospital & Pet Resort

INTERPRETATION OF THE FINDINGS & FURTHER RECOMMENDATIONS

There is evidence of generalized advanced periodontal disease of all teeth and oronasal fistula formation of triadan 208 with secondary left sided destructive rhinitis. A complete dental workup and extraction of the affected teeth is recommended.

REFERRING VET

Rupashree Rao

INVOICE

51970

DATE

5-7-22



PATIENT

Shadow Vargas

SPECIES

Canine

BREED

Mixed Breed

SEX

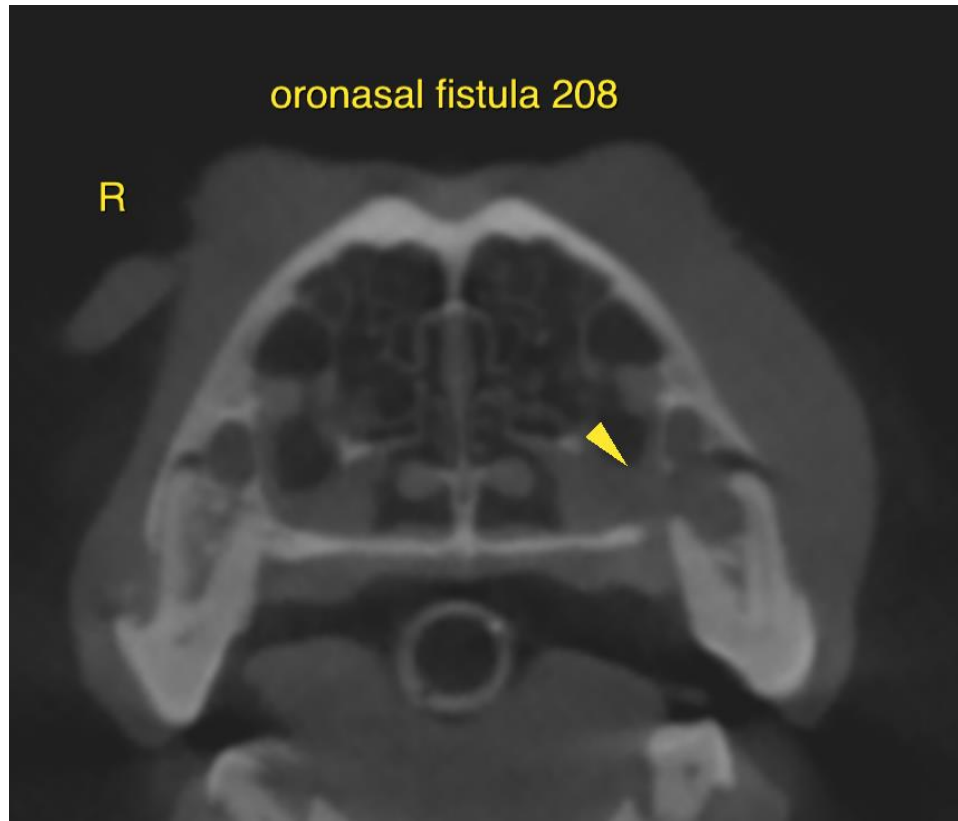
Male Neutered

AGE

11 Years

INTERPRETED BY

Sebastian Schaub, DVM
Dr. med. vet. DipECVDI

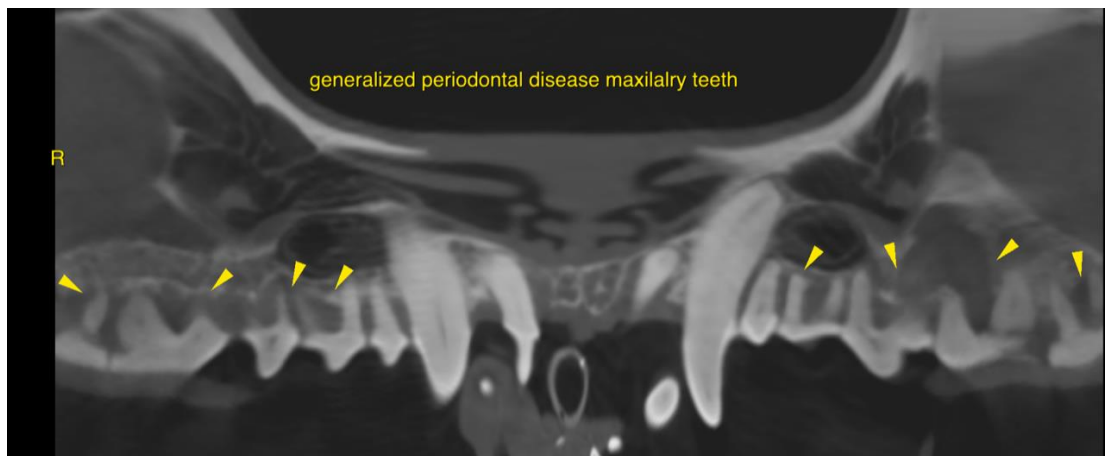


HOSPITAL NAME

South Bay Animal
Hospital & Pet Resort

REFERRING VET

Rupashree Rao



INVOICE

51970

DATE

5-7-22



PATIENT

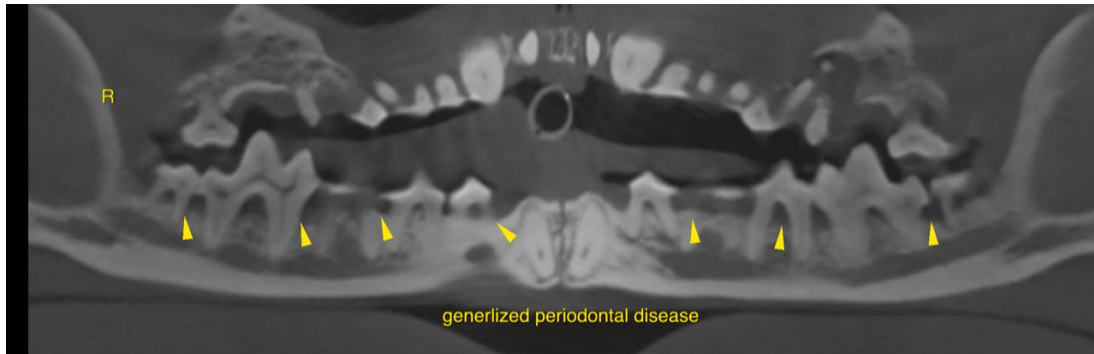
Shadow Vargas

SPECIES

Canine

BREED

Mixed Breed



SEX

Male Neutered

AGE

11 Years

INTERPRETED BY

Sebastian Schaub, DVM
Dr. med. vet. DipECVDI

HOSPITAL NAME

South Bay Animal
Hospital & Pet Resort

REFERRING VET

Rupashree Rao

INVOICE

51970

DATE

5-7-22

The information and recommendations provided are based on the images presented by the referring veterinarian/sonographer. No evaluation can be communicated regarding pathology that was not visible in the image/video clips provided.

Thank you for this referral. If the clinical or image interpretation does not parallel your findings or if I can be of any further assistance please contact me.

Sebastian Schaub, Sebastian Schaub, DVM, Dr. med. vet. DipECVDI
sebast.schaub@gmail.com