



PATIENT PRESENTING CLINICAL SIGNS

Penelope Egan-Leary Chronic lameness right thoracic limb

RADIOGRAPHIC STUDY OF THE RIGHT ELBOW JOINT

SPECIES A mediolateral view of the right elbow joint is provided for review.

Canine **RADIOGRAPHIC FINDINGS**

The periarticular bones of the right elbow joint present advanced osteophyte new bone formation. The contour of the medial coronoid process cannot be defined. The surrounding soft tissue structures present without abnormalities.

BREED

Boston Terrier Mix **RADIOGRAPHIC DIAGNOSIS**

- Advanced degenerative osteoarthritis right elbow joint

SEX

INTERPRETATION OF THE FINDINGS & FURTHER RECOMMENDATIONS

Female Spayed

The degenerative joint disease of the right elbow joint would be a plausible source for the chronic right front limb lameness. Underlying coronoid disease might be present.

AGE

10 Years

INTERPRETED BY

Sebastian Schaub, DVM
Dr. med. vet. DipECVDI

HOSPITAL NAME

New Bridge
Veterinary Practice

REFERRING VET

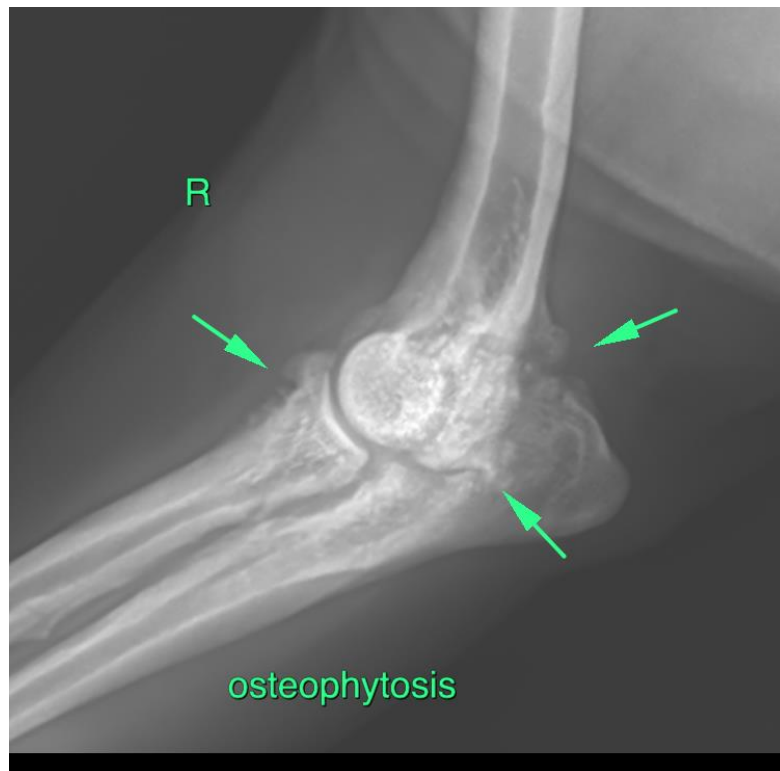
Dr. Abina Glennon

INVOICE

58148

DATE

5-5-23





PATIENT

Penelope Egan-Leary

SPECIES

Canine

The information and recommendations provided are based on the images presented by the referring veterinarian/sonographer. No evaluation can be communicated regarding pathology that was not visible in the image/video clips provided.

Thank you for this referral. If the clinical or image interpretation does not parallel your findings or if I can be of any further assistance please contact me.

BREED

Boston Terrier Mix

Sebastian Schaub, Sebastian Schaub, DVM, Dr. med. vet. DipECVDI
sebast.schaub@gmail.com

SEX

Female Spayed

AGE

10 Years

INTERPRETED BY

Sebastian Schaub, DVM
Dr. med. vet. DipECVDI

HOSPITAL NAME

New Bridge
Veterinary Practice

REFERRING VET

Dr. Abina Glennon

INVOICE

58148

DATE

5-5-23