



PATIENT PRESENTING CLINICAL SIGNS

Kesha Hertz several week history of weight loss and decreased appetite. increase in vomiting (Several times per week - usually undigested food). Diagnosed with allergic bronchitis 3-4 months ago and improved after steroid trial. Bloodwork on 5/3/23 (SDMA - 17mcg/dl (0-14), Calcium 13.9 mg/dl (7.8-11.3), globulins 5.1g/dl (2.8-5.1) WBC - 18k (2.8-17), monocytes 0.73 (.05-0.67). Ionized calcium and hypercalcemia panel pending.

Feline

COMPUTED TOMOGRAPHY OF THE SKULL, THORAX AND ABDOMEN

BREED

A high resolution pre- and post-contrast CT study of the skull, thorax and abdomen is provided for review.

Siamese Mix

COMPUTED TOMOGRAPHIC FINDINGS

Skull

SEX

Multiple teeth are absent.

FS

The nasal cavity presents the expected aerated spaces between thin & even conchae and turbinates with smooth mucosal lining.

AGE

Both temporomandibular joints present congruent joint spaces with even subchondral bone surfaces and are considered within normal limits.

11

Both tympanic bullae are aerated, the mucosal lining is not seen, the bony wall is smooth and thin. The external ear canals are within normal limits.

INTERPRETED BY

The brain presents no deviation from normal anatomy and symmetry. The brain parenchyma is homogeneous and within normal limits for attenuation and distribution of contrast enhancement. The ventricular system is non-dilated and symmetric.

Sebastian Schaub, DVM
Dr. med. vet. DipECVDI

HOSPITAL NAME

The submandibular and medial retropharyngeal lymph nodes are small and elongated with a normal short-to-long-axis-ratio is < 0.5, the attenuation and contrast enhancement pattern is uniform.

Scottsdale Veterinary
Clinic

The osseous and soft tissue structures of the neck are unremarkable.

Thorax

REFERRING VET

The vertebral endplates T11/T12 present moderate spondylosis formation.

Dr. Hertz

The left sternal lymph node is mildly prominent.

The cardiovascular structures including the pulmonary vasculature are within normal limits.

INVOICE

The bronchial walls are generalized mildly thickened.

58145

In the caudal aspect of the right caudal lung lobe, adjacent to the diaphragm, an ill-defined zone with consolidation of the lung parenchyma is seen, the volume of the respective region appears decreased. The remainder of the lung parenchyma present the expected architecture and attenuation behavior.

DATE

Small incidental gas pockets are seen within the esophageal lumen, there is no evidence of abnormal dilation.

5-5-23

Abdomen

The serosal fat presents normal attenuation behavior. There is no evidence of peritoneal effusion or



PATIENT peritonitis.

Kesha Hertz Both kidneys present within normal limits for size, shape and organ architecture. After contrast administration a bilaterally symmetric and uniform nephro- and pyelogram is noted.

SPECIES The adrenal glands are within normal limits for size, shape and organ architecture.

Feline Both liver and spleen present with normal shape, even surface, uniformly attenuating parenchyma and homogeneous contrast enhancement, unremarkable.

BREED The left lobe of the pancreas presents segmental significant decreased volume of the parenchyma resulting in feathered appearance caused by fat interspersed between the pancreatic lobules.

Siamese Mix Post contrast administration, the outer layer of the wall of the ilium – suspect muscular layer – is prominent. The position, delineation, wall and content of the remainder of the gastrointestinal tract are considered within normal limits throughout.

SEX The jejunal lymph node is prominent and has a mild irregular contrast enhancement pattern.

FS The bony and surrounding soft tissue structures reveal no abnormalities.

COMPUTED TOMOGRAPHIC DIAGNOSIS

- AGE** 11
- Circumferential mural thickening wall ilium
 - Lymphadenopathy jejunal lymph node and sternal lymph node
 - Atrophy of the pancreas
 - Mild bronchial lung pattern
 - Area of pulmonary consolidation right caudal lung lobe with decreased volume
 - History of dental extractions

INTERPRETED BY

Sebastian Schaub, DVM
Dr. med. vet. DipECVDI

INTERPRETATION OF THE FINDINGS & FURTHER RECOMMENDATIONS

HOSPITAL NAME

Scottsdale Veterinary
Clinic

The prominent wall of the ilium can still present a normal anatomical variant or indicates inflammation (e.g. ileitis, lymphocytic plasmocytic, eosinophilic inflammatory infiltration) versus neoplastic invasion (e.g. round cell tumor). The prominent jejunal and sternal lymph node are not specific, but the odds for reactive hyperplasia are considered higher than for neoplastic infiltration. Recommend ultrasound guided FNA sampling of the jejunal lymph node for further definition.

REFERRING VET

Dr. Hertz

The bronchial pattern and region of pulmonary consolidation are fitting the history of feline bronchial disease – commonly primary allergic – with zone of atelectasis focal pneumonia right caudal lung lobe.

The clinical relevance of the pancreas is unclear and is commonly a sequela to chronic pancreatitis. Rule out underlying acute on chronic pancreatitis as source for the presenting clinical signs.

INVOICE

58145

DATE

5-5-23



PATIENT

Kesha Hertz

SPECIES

Feline

BREED

Siamese Mix

SEX

FS

AGE

11

INTERPRETED BY

Sebastian Schaub, DVM
Dr. med. vet. DipECVDI

HOSPITAL NAME

Scottsdale Veterinary
Clinic

REFERRING VET

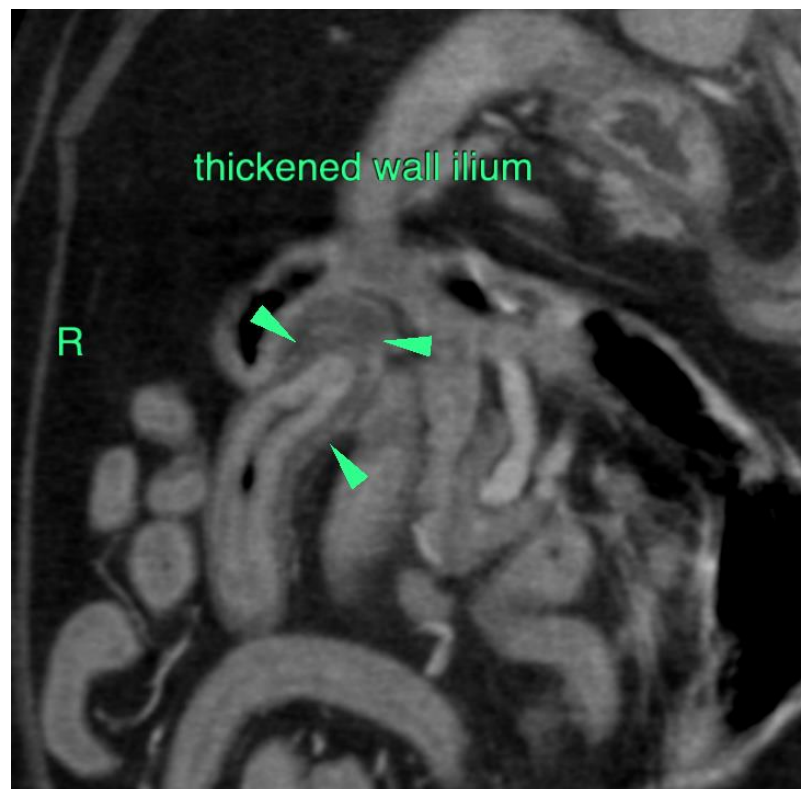
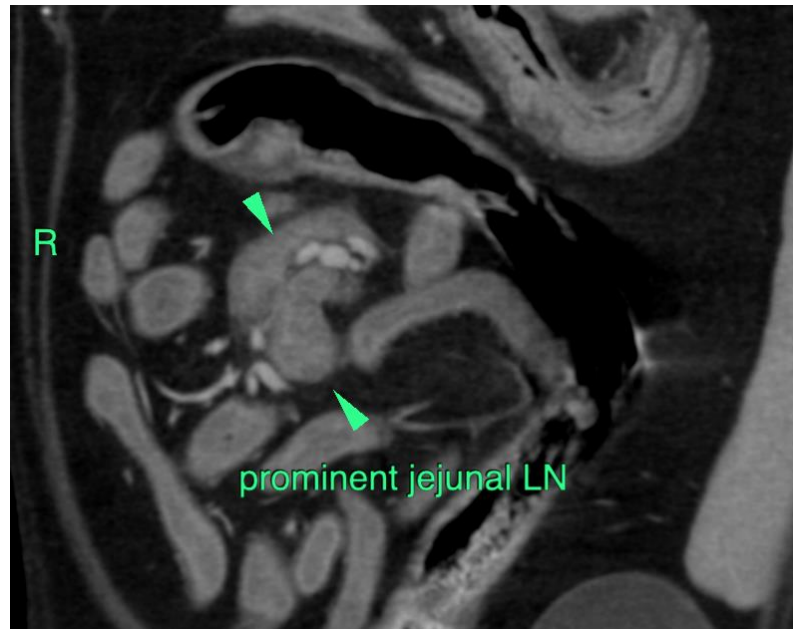
Dr. Hertz

INVOICE

58145

DATE

5-5-23





PATIENT

Kesha Hertz

SPECIES

Feline

BREED

Siamese Mix

SEX

FS

AGE

11

INTERPRETED BY

Sebastian Schaub, DVM
Dr. med. vet. DipECVDI

HOSPITAL NAME

Scottsdale Veterinary
Clinic

REFERRING VET

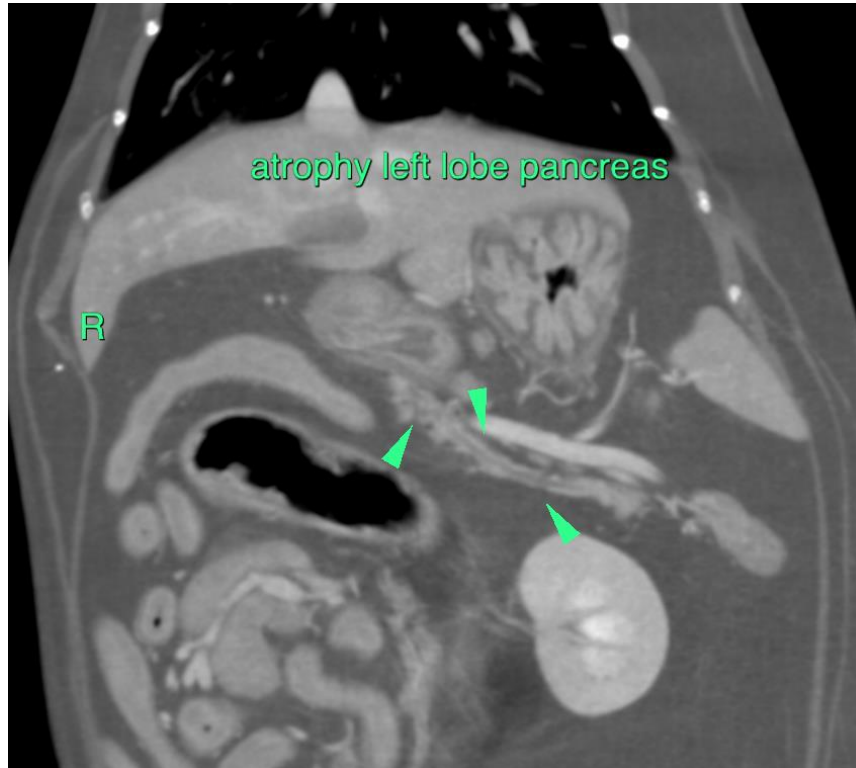
Dr. Hertz

INVOICE

58145

DATE

5-5-23



The information and recommendations provided are based on the images presented by the referring veterinarian/sonographer. No evaluation can be communicated regarding pathology that was not visible in the image/video clips provided.

Thank you for this referral. If the clinical or image interpretation does not parallel your findings or if I can be of any further assistance please contact me.

Sebastian Schaub, Sebastian Schaub, DVM, Dr. med. vet. DipECVDI
sebast.schaub@gmail.com