



PATIENT PRESENTING CLINICAL SIGNS

PATIENT Marvin Hekhuis
SPECIES History: Marvin presents for a swollen eye and painful mouth. How long has problem been going on: O left NC monday afternoon, has not had any issues since they left. P was not really interested in eating last night and refused to eat this morning. P did drink a little bit this morning. Sometime does have pumpkin due to having diarrhea often. P is not in a fenced in yard, has land to run around on. P has lost use of L eye 3 years ago due to molar abscess
BREED Canine
SEX Abnormal PE/Chem/CBC/UA Results:

COMPUTED TOMOGRAPHIC STUDY OF THE SKULL

BREED Airedale Terrier
 A high resolution pre- and post-contrast CT study of the is provided for review.

COMPUTED TOMOGRAPHIC FINDINGS

SEX The tooth elements 203, 308 and 406 are absent.
AGE Male
 A generalized moderate subcutaneous swelling along the skull is noted, most accentuated along the right aspect of the skull. In the right retrobulbar region, affecting the rostral part of the right temporal muscle and pterygoid muscle, a large, irregular marginated, fluid attenuating swelling is appreciated, measuring 9.2 x 3.4 x 3.5 cm in size. The swelling bulging orally, caudal to the last right maxillary molar tooth and is extending laterally into the right masseter muscle. The right ocular bulb is deviated rostrally by the mass effect. Dorsally, the fluid attenuating swelling is extending up into the subcutaneous tissue. The surrounding musculature presents moderate heterogeneous contrast enhancement.
INTERPRETED BY 12 Years

INTERPRETED BY Sebastian Schaub, DVM Dr. med. vet. DipECVDI
 The nasal cavity presents the expected aerated spaces between thin & even conchae and turbinates with smooth mucosal lining.

HOSPITAL NAME Both temporomandibular joints present congruent joint spaces with even subchondral bone surfaces and are considered within normal limits.

Neel VH Both tympanic bullae are aerated, the mucosal lining is not seen, the bony wall is smooth and thin. The external ear canals are within normal limits.

REFERRING VET Dr. Ellen Domnick
 The brain presents no deviation from normal anatomy and symmetry. The brain parenchyma is homogeneous and within normal limits for attenuation and distribution of contrast enhancement. The ventricular system is non-dilated and symmetric.

INVOICE The mandibular lymph nodes and the right medial retropharyngeal lymph node are mild to moderately enlarged.

15063 **COMPUTED TOMOGRAPHIC DIAGNOSIS**

- Right sided retrobulbar, large irregular marginated cavitory lesion

DATE

5/5/22



PATIENT

Marvin Hekhuis

- Generalized edematous swelling along the skull
- Secondary right sided exophthalmos
- Lymphadenopathy mandibular lymph nodes and right medial retropharyngeal lymph node
- Absent triadan 203, 308 and 406

SPECIES

Canine

BREED

Airedale Terrier

INTERPRETATION OF THE FINDINGS & FURTHER RECOMMENDATIONS

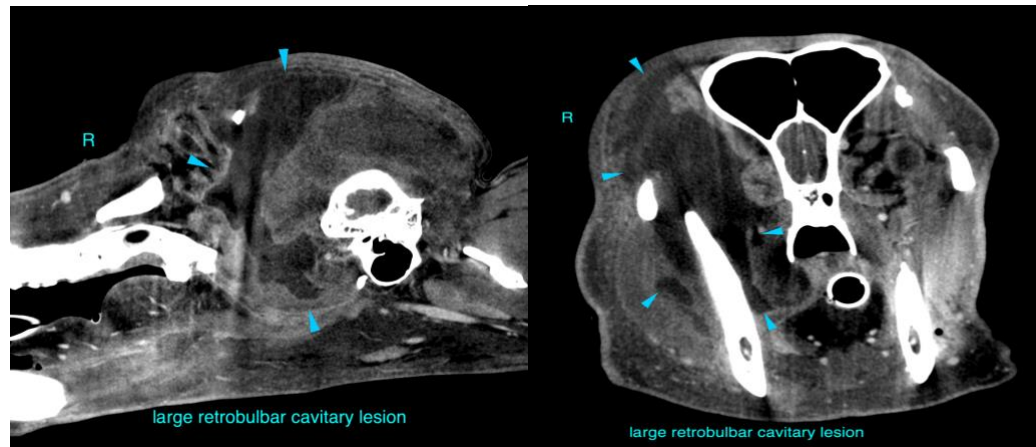
The CT study is compatible with a right sided large retrobulbar abscess and secondary inflammatory edematous swelling along the skull and reactive hyperplasia of the regional lymph nodes. An underlying cause for the abscess is not appreciated and a preceding perforating trauma or migrating foreign (isoattenuating to the surrounding material) body are potentials. Ultrasound can be used to screen for foreign material and surgical drainage is the therapy of choice.

SEX

Male

AGE

12 Years



INTERPRETED BY

Sebastian Schaub,
DVM Dr. med. vet.
DipECVDI

The information and recommendations provided are based on the images presented by the referring veterinarian/sonographer. No evaluation can be communicated regarding pathology that was not visible in the image/video clips provided.

HOSPITAL NAME

Neel VH

Thank you for this referral. If the clinical or image interpretation does not parallel your findings or if I can be of any further assistance please contact me.

REFERRING VET

Dr. Ellen Domnick

Sebastian Schaub, Sebastian Schaub, DVM, Dr. med. vet. DipECVDI
sebast.schaub@gmail.com

INVOICE

15063

DATE

5/5/22



PATIENT

Marvin Hekhuis

SPECIES

Canine

BREED

Airedale Terrier

SEX

Male

AGE

12 Years

INTERPRETED BY

Sebastian Schaub,
DVM Dr. med. vet.
DipECVDI

HOSPITAL NAME

Neel VH

REFERRING VET

Dr. Ellen Domnick

INVOICE

15063

DATE

5/5/22