

**PATIENT**

Mango Nicholas

PRESENTING CLINICAL SIGNS

URI/epistaxis

SPECIES

Canine

COMPUTED TOMOGRAPHY OF THE SKULL

A high resolution pre- and post-contrast CT study of the skull is provided for review.

BREED

English Bulldog

COMPUTED TOMOGRAPHIC FINDINGS

A bradygnathia superior is noted.

The tooth elements 205-207, 311, 405 and 411 are absent. The periodontal space of triadan 105 to 107 is markedly widened and the roots are perforating the right nasal cavity; local soft tissue swelling is seen in the lateroventral aspect of the right nasal cavity.

Triadan 101&201 present a moderate widening of the alveolar crest mesially. Ankylosis of the roots of the upper incisors is appreciated.

SEX

FS

The distal root of triadan 410 presents a marked widening of the periodontal space.

Both temporomandibular joints present congruent joint spaces with even subchondral bone surfaces and are considered within normal limits.

AGE

10

COMPUTED TOMOGRAPHIC DIAGNOSIS

- Marked periodontal disease 105-107 with oronasal fistula formation
- Secondary right sided destructive rhinitis
- Advanced periodontal disease upper incisors and triadan 410
- Bradygnathia superior

INTERPRETED BYSebastian Schaub, DVM
Dr. med. vet. DipECVDI**INTERPRETATION OF THE FINDINGS & FURTHER RECOMMENDATIONS**

The oronasal fistula formation caused by periodontal disease of triadan 105-107 with secondary odontogenic rhinitis is a plausible explanation for the presenting clinical signs. Recommend complete dental workup, with extraction and surgical closure of the oronasal fistulas.

HOSPITAL NAMEStone Cottage
Veterinary Hospital**REFERRING VET**

Spaccarelli

INVOICE

51947

DATE

5-5-22



PATIENT

Mango Nicholas

SPECIES

Canine

BREED

English Bulldog

SEX

FS

AGE

10

INTERPRETED BY

Sebastian Schaub, DVM
Dr. med. vet. DipECVDI

HOSPITAL NAME

Stone Cottage
Veterinary Hospital

REFERRING VET

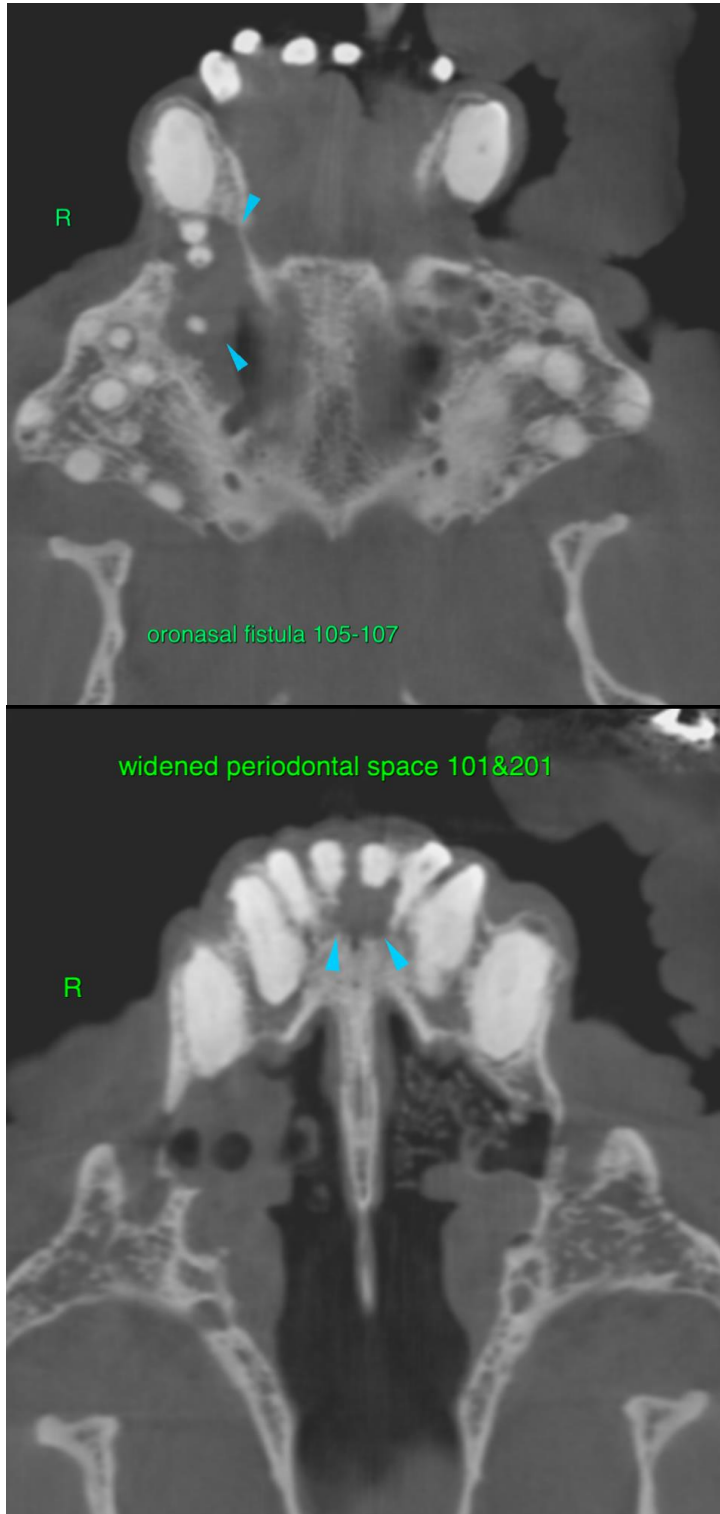Spaccarelli

INVOICE

51947

DATE

5-5-22





PATIENT

Mango Nicholas

SPECIES

Canine

BREED

English Bulldog

SEX

FS

AGE

10

INTERPRETED BY

Sebastian Schaub, DVM
Dr. med. vet. DipECVDI

HOSPITAL NAME

Stone Cottage
Veterinary Hospital

REFERRING VET

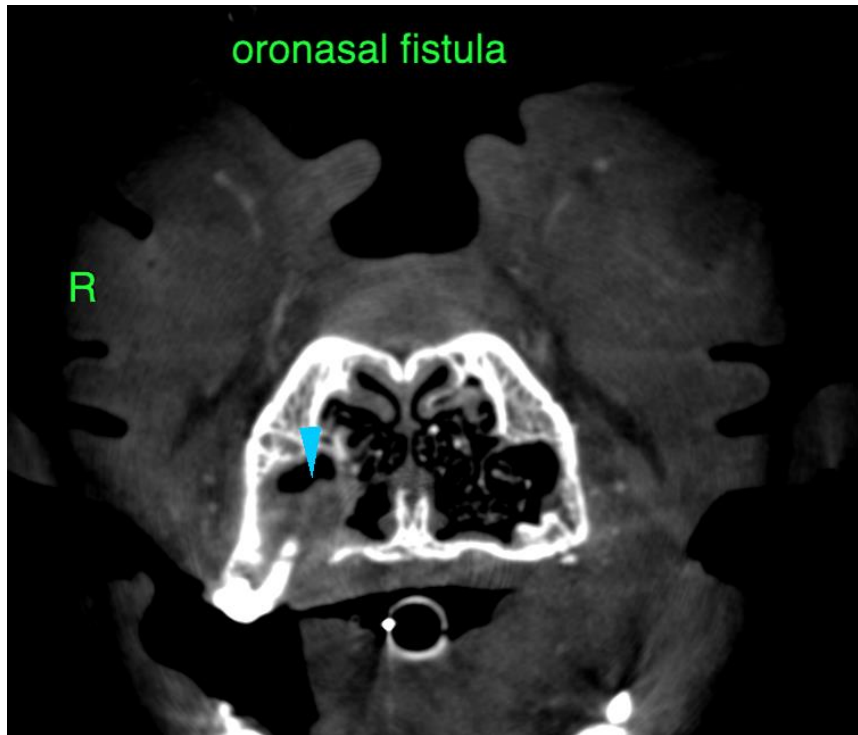
Spaccarelli

INVOICE

51947

DATE

5-5-22



The information and recommendations provided are based on the images presented by the referring veterinarian/sonographer. No evaluation can be communicated regarding pathology that was not visible in the image/video clips provided.

Thank you for this referral. If the clinical or image interpretation does not parallel your findings or if I can be of any further assistance please contact me.

Sebastian Schaub, Sebastian Schaub, DVM, Dr. med. vet. DipECVDI
sebast.schaub@gmail.com