



PATIENT PRESENTING CLINICAL SIGNS

Dexter Carmenate History: Pet was inside a moving car when owner had to brake hard, and the pets may have been injured. Doing much better on medication.
Abnormal PE/Chem/CBC/UA Results: Ambulatory x 4

SPECIES COMPUTED TOMOGRAPHIC STUDY OF THE ENTIRE SPINE

Canine A high resolution pre- and post-contrast CT study of the cervical, thoracic and lumbar spine is provided for review.

BREED COMPUTED TOMOGRAPHIC FINDINGS

Bully The external ear canals bilaterally present a moderate thickening of the wall and the external ear canals bilaterally are significantly narrowed.

SEX
Intact Male The vertebral endplates along the caudal cervical spine present mild spondylosis formation. The vertebral body of T9 has a wedge-shaped conformation.

AGE
3 Years The vertebral endplates L1/L2 show mild spondylosis formation.

The intervertebral disc L6/L7 is moderately protruding into the vertebral canal, occupying approximately 50% of the cross-sectional area of the vertebral canal at the same level.

INTERPRETED BY Sacralization of L7 is noted, articulating bilaterally with the sacroiliac joint.

Sebastian Schaub, DVM
Dr. med. vet. DipECVDI The acetabular groove bilaterally is shallow.

COMPUTED TOMOGRAPHIC DIAGNOSIS

HOSPITAL NAME

Mobile Pet Imaging

- Moderate intervertebral disc protrusion L6/L7 with potential dynamic compression of the caudal equina fibers
- Symmetric lumbosacral transitional vertebra (type II)
- Moderate Hip dysplasia
- Otitis externa bilaterally
- Hemivertebra T9
- Multifocal mild spondylosis formation, marked level L6/L7

REFERRING VET

Dr. Meaux

INTERPRETATION OF THE FINDINGS & FURTHER RECOMMENDATIONS

INVOICE

15088

The CT study presents without signs for acute intervertebral disc disease or fracture. If there is strong suspicion for compressive myelopathy, complementing workup by a myelographic CT study is recommended.

DATE

5/5/22



PATIENT

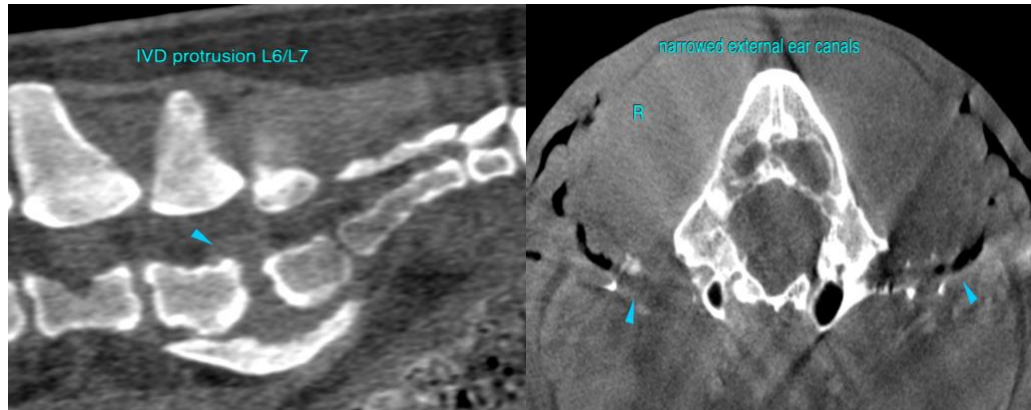
Dexter Carmenate

SPECIES

Canine

BREED

Bully



SEX

Intact Male

AGE

3 Years

The information and recommendations provided are based on the images presented by the referring veterinarian/sonographer. No evaluation can be communicated regarding pathology that was not visible in the image/video clips provided.

Thank you for this referral. If the clinical or image interpretation does not parallel your findings or if I can be of any further assistance please contact me.

Sebastian Schaub, Sebastian Schaub, DVM, Dr. med. vet. DipECVDI
sebast.schaub@gmail.com

INTERPRETED BY

Sebastian Schaub, DVM
Dr. med. vet. DipECVDI

HOSPITAL NAME

Mobile Pet Imaging

REFERRING VET

Dr. Meaux

INVOICE

15088

DATE

5/5/22