



PATIENT

Carson White

PRESENTING CLINICAL SIGNS

Dx by needle aspirates with lymphoma. Has had a soft cough for a few months. Chest rads submitted for review.

SPECIES

Canine

RADIOGRAPHIC STUDY OF THE THORAX

Radiographs of the thorax in two imaging planes are provided for review.

BREED

Dutch Shepherd

RADIOGRAPHIC FINDINGS

The periarticular bones of both shoulder joints present moderate osteophyte new bone formation.

Two microchip implants are superimposed on one scapula. Part of the metal opaque, clamp like body is seen superimposed on the cranial abdomen in the lateral view.

SEX

MN

The heart is of normal size and shape, there is no evidence of cardiac chamber or vascular enlargement. The pulmonary vasculature is within normal limits.

The cranial mediastinum presents the expected soft tissue opacity. The mediastinal width is less than twice the width of the vertebral column at the same level.

AGE

10

The trachea is normal in diameter and presents the anticipated course. The luminal outline of the trachea is smooth.

INTERPRETED BY

Sebastian Schaub, DVM
Dr. med. vet. DipECVDI

The bronchial tree presents with thin walls and tapers uniformly towards the periphery as expected.

The lung parenchyma presents the expected architecture and opacity; the intrapulmonary vascular branching is seen up to the third order lung vessels.

The diaphragm is well delineated with even surface and the expected mild cranial bulging of the diaphragmatic cupola.

HOSPITAL NAME

Healing Paws

RADIOGRAPHIC DIAGNOSIS

- Possible small metal opaque foreign body cranial abdomen versus cutaneous skin staple
- Degenerative osteoarthritis shoulder joints bilaterally

REFERRING VET

Jennifer Levitsky

INTERPRETATION OF THE FINDINGS & FURTHER RECOMMENDATIONS

The lung parenchyma/bronchial tree present without abnormalities, explaining the described cough. However, negative radiographs do not rule out inflammatory lower airway disease entirely.

INVOICE

51956

DATE

5-5-22



PATIENT

Carson White

SPECIES

Canine

BREED

Dutch Shepherd

SEX

MN

AGE

10

INTERPRETED BY

Sebastian Schaub, DVM
Dr. med. vet. DipECVDI

HOSPITAL NAME

Healing Paws

REFERRING VET

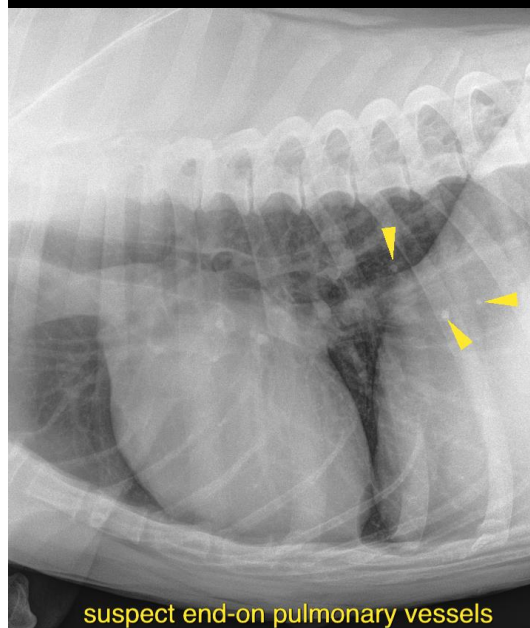
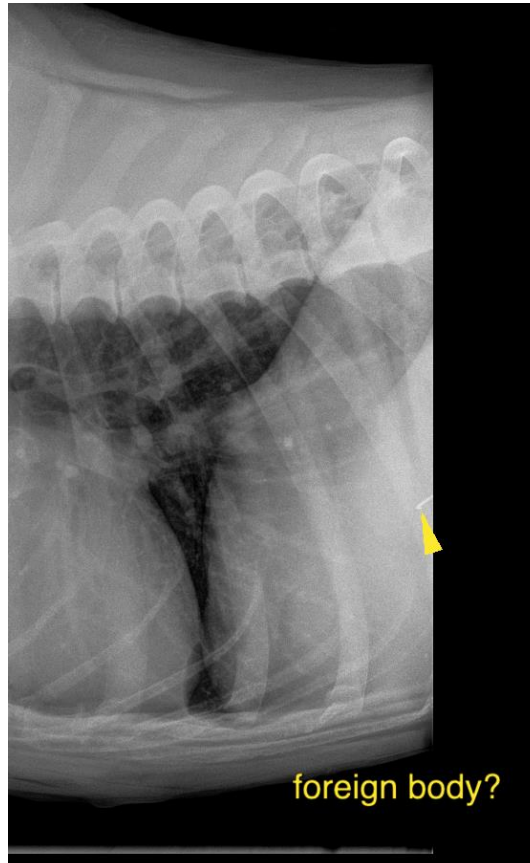
Jennifer Levitsky

INVOICE

51956

DATE

5-5-22





PATIENT

Carson White

SPECIES

Canine

BREED

Dutch Shepherd

SEX

MN

AGE

10

INTERPRETED BY

Sebastian Schaub, DVM
Dr. med. vet. DipECVDI

HOSPITAL NAME

Healing Paws

REFERRING VET

Jennifer Levitsky

INVOICE

51956

DATE

5-5-22

The information and recommendations provided are based on the images presented by the referring veterinarian/sonographer. No evaluation can be communicated regarding pathology that was not visible in the image/video clips provided.

Thank you for this referral. If the clinical or image interpretation does not parallel your findings or if I can be of any further assistance please contact me.

Sebastian Schaub, Sebastian Schaub, DVM, Dr. med. vet. DipECVDI
sebast.schaub@gmail.com