

**PATIENT**

Ash Bouffard

SPECIES

Canine

BREED

Standard Poodle

SEX

MN

AGE

9 Years

INTERPRETED BYSebastian Schaub, DVM
Dr. med. vet. DipECVDI**HOSPITAL NAME**Balmy Beach Pet
Hospital**REFERRING VET**

Dr. Singh

INVOICE

51936

DATE

5-5-22

PRESENTING CLINICAL SIGNS

Presented with a firm swelling on the left side of the head, with left sided hemorrhagic nasal discharge. Has been going on for the last month or so. Eating and drinking well, no weight loss. Abnormal PE/Chem/CBC/UA Results: Bloodwork results WNL Took punch biopsies of the lump, results pending.

RADIOGRAPHIC STUDY OF THE SKULL

Radiographs of the skull in two orthogonal imaging planes are provided for review.

RADIOGRAPHIC FINDINGS

In the VD projection, the lateral aspect of the left frontal sinus presents an increased opacity, and the lateral osseous margins are irregular with moth eaten osteolytic lesions. In the lateral projection, a roundish soft tissue to mineral opaque structure is superimposed on the frontal sinuses. In the lateral projection, the dorsal osseous lamella of the frontal bone of – likely the left side – presents permeative osteolytic lesions.

No additional abnormalities.

RADIOGRAPHIC DIAGNOSIS

- Suspect mass left frontal sinus with osteolytic lesions of the left frontal bone

INTERPRETATION OF THE FINDINGS & FURTHER RECOMMENDATIONS

The findings are highly concerning for neoplastic disease originating from the left frontal sinus with secondary osteolysis. FNA sampling of the swelling can be used as minimally invasive diagnostic test. A CT study of the skull can also be used for further assessment of the extend of the suspected mass.



PATIENT

Ash Bouffard

SPECIES

Canine

BREED

Standard Poodle

SEX

MN

AGE

9 Years

INTERPRETED BY

Sebastian Schaub, DVM
Dr. med. vet. DipECVDI

HOSPITAL NAME

Balmy Beach Pet
Hospital

REFERRING VET

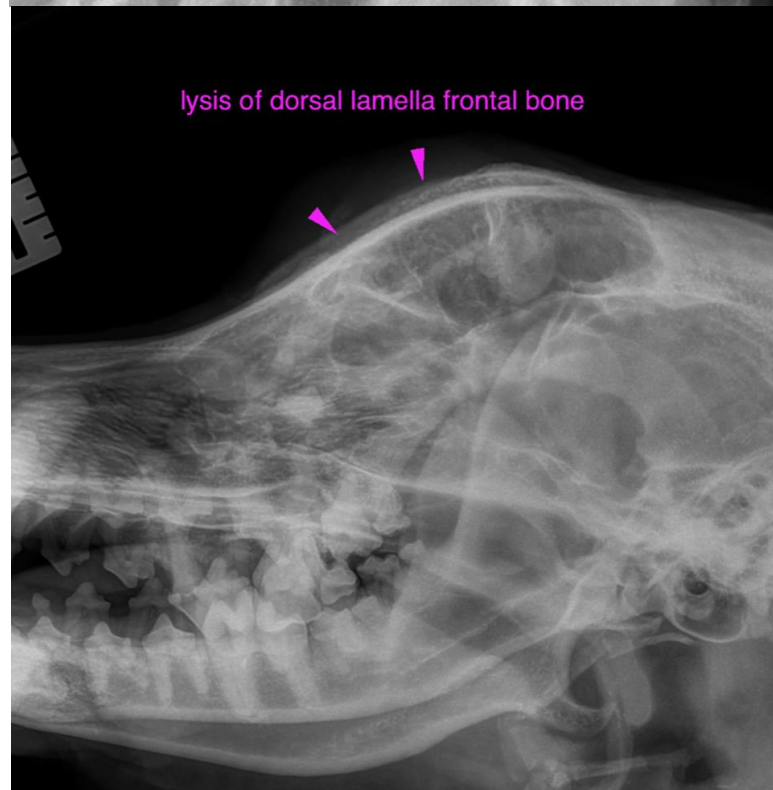
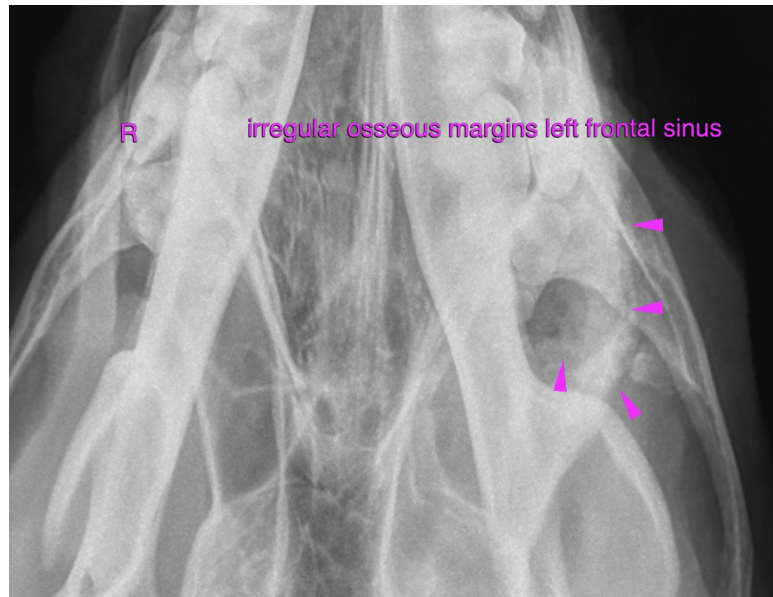
Dr. Singh

INVOICE

51936

DATE

5-5-22





PATIENT

Ash Bouffard

SPECIES

Canine

BREED

Standard Poodle

SEX

MN

AGE

9 Years

INTERPRETED BY

Sebastian Schaub, DVM
Dr. med. vet. DipECVDI

HOSPITAL NAME

Balmy Beach Pet
Hospital

REFERRING VET

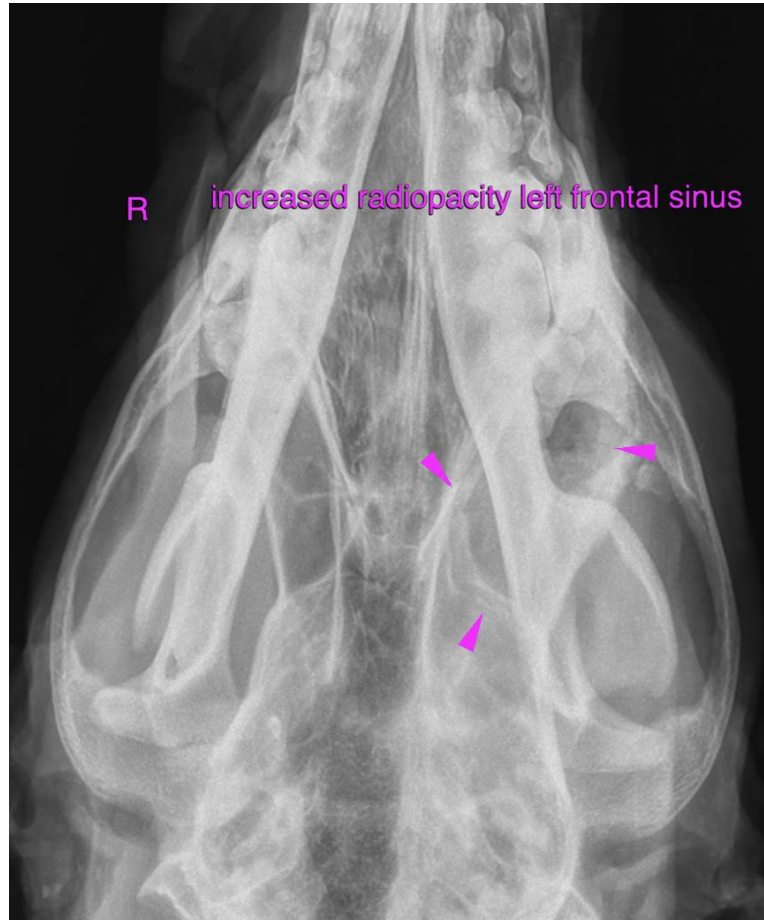
Dr. Singh

INVOICE

51936

DATE

5-5-22



The information and recommendations provided are based on the images presented by the referring veterinarian/sonographer. No evaluation can be communicated regarding pathology that was not visible in the image/video clips provided.

Thank you for this referral. If the clinical or image interpretation does not parallel your findings or if I can be of any further assistance please contact me.

Sebastian Schaub, Sebastian Schaub, DVM, Dr. med. vet. DipECVDI
sebast.schaub@gmail.com