

**PATIENT**

Sutera Galloway

PRESENTING CLINICAL SIGNS

HBC INJURY. STILL LIMPING. LEFT FRONT.

COMPUTED TOMOGRAPHY OF THE FRONT LIMBS**SPECIES**

Canine

A high resolution pre- and post-contrast CT study of the front limbs is provided for review.

BREED

Australian Shepard

COMPUTED TOMOGRAPHIC FINDINGS

In the mid segment of the spinous process of T1, a transverse fracture with mild callus formation is appreciated.

The volume of the musculature of the left front limb is moderately decreased.

The shoulder, elbow and carpal joints present smooth osseous margins, unremarkable.

SEX

Spayed Female

COMPUTED TOMOGRAPHIC DIAGNOSIS

- Chronic traumatic non-displaced transverse fracture spinous process T1, in the reparation phase
- Disuse atrophy left front limb

AGE

2 Years, 3 Months

INTERPRETATION OF THE FINDINGS & FURTHER RECOMMENDATIONS

The CT study of the front limbs presents without abnormalities, explaining the left front limb lameness. No overt abnormalities along the cervical spine appreciated as well. Rule out soft tissue damage or any nerval laceration/compression as cause for the clinical signs as well – the fracture of the spinous process of T1 may indicate trauma to the brachial plexus. An ultrasound examination or MRI study of the brachial plexus & cervical spine can be considered as advanced imaging modalities.

INTERPRETED BYSebastian Schaub, DVM
Dr. med. vet. DipECVDI**HOSPITAL NAME**Aloha Pet & Bird
Hospital**REFERRING VET**

Rebecca Smith

INVOICE

51898

DATE

5-4-22



PATIENT

Sutera Galloway

SPECIES

Canine

BREED

Australian Shepard

SEX

Spayed Female

AGE

2 Years, 3 Months

INTERPRETED BY

Sebastian Schaub, DVM
Dr. med. vet. DipECVDI

HOSPITAL NAME

Aloha Pet & Bird
Hospital

REFERRING VET

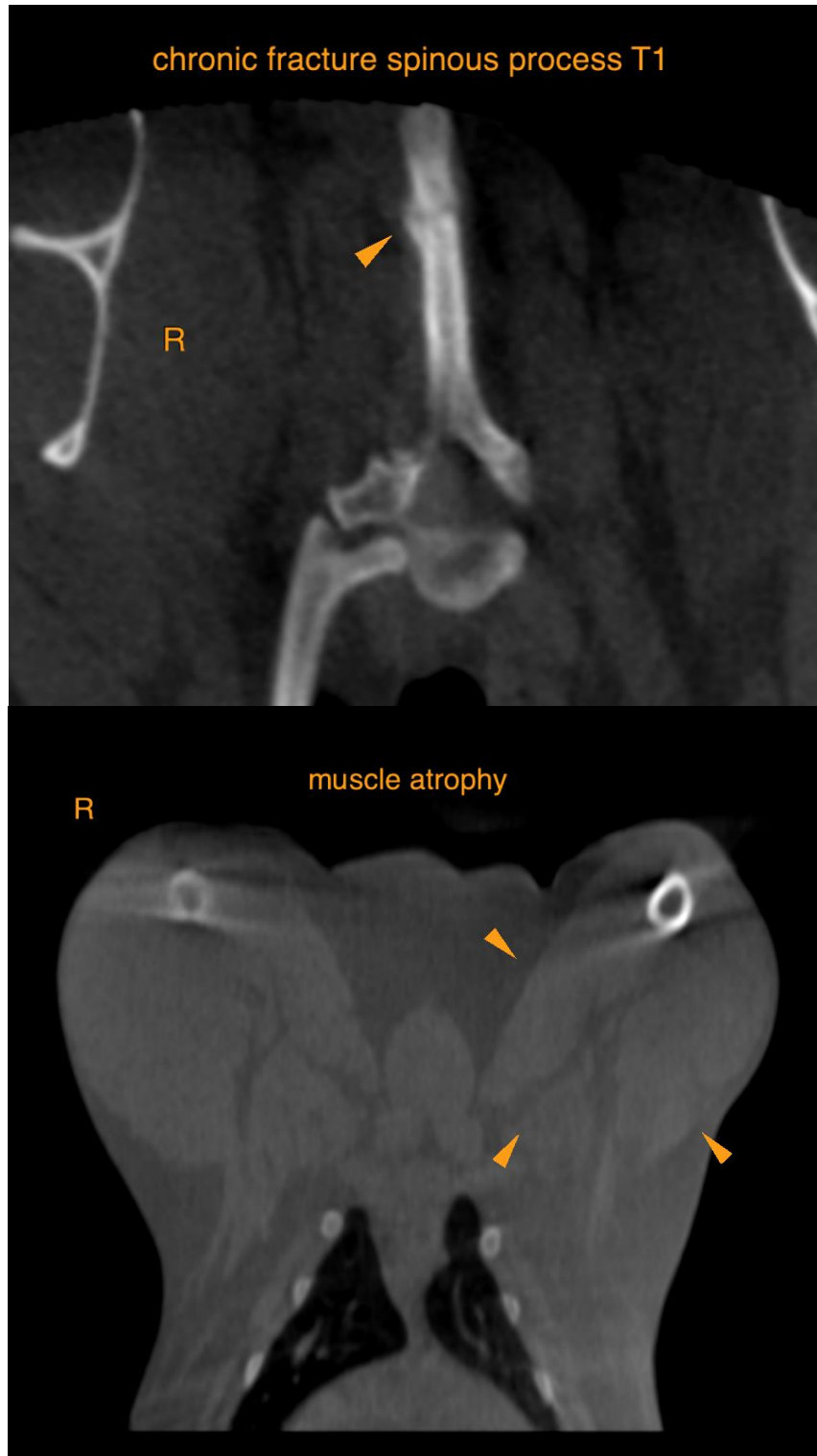
Rebecca Smith

INVOICE

51898

DATE

5-4-22





PATIENT

Sutera Galloway

The information and recommendations provided are based on the images presented by the referring veterinarian/sonographer. No evaluation can be communicated regarding pathology that was not visible in the image/video clips provided.

SPECIES

Canine

Thank you for this referral. If the clinical or image interpretation does not parallel your findings or if I can be of any further assistance please contact me.

BREED

Australian Shepard

Sebastian Schaub, Sebastian Schaub, DVM, Dr. med. vet. DipECVDI
sebast.schaub@gmail.com

SEX

Spayed Female

AGE

2 Years, 3 Months

INTERPRETED BY

Sebastian Schaub, DVM
Dr. med. vet. DipECVDI

HOSPITAL NAME

Aloha Pet & Bird
Hospital

REFERRING VET

Rebecca Smith

INVOICE

51898

DATE

5-4-22