

**PATIENT**

Skeeter Swenson

SPECIES

Canine

BREED

Springer Spaniel

SEX

Male Neutered

AGE

8 Years

INTERPRETED BYSebastian Schaub, DVM
Dr. med. vet. DipECVDI**HOSPITAL NAME**State Avenue Vet
Clinic**REFERRING VET**

Dr. Raul Casas-Dolz

INVOICE

51928

DATE

5-4-22

PRESENTING CLINICAL SIGNS

Hx of lethargy, ataxia and neck pain; has been whining and stiff; reluctant to jump
Abnormal PE/Chem/CBC/UA Results: BAR; p/m mm; CRT 1-2s; no mur/arrh; no abn lung sounds;
no abd dist; no pain or abns on abd palp; eyes, ears, LNs WNL; ambulating normally; CPs WNL; no
pain on palpation of neck; sl tense with full ROM of neck; placed under GA; obtained survey CT
and performed myelogram

COMPUTED TOMOGRAPHY OF THE NECK

A high resolution plain and myelographic CT study of the neck is provided for review.

COMPUTED TOMOGRAPHIC FINDINGS

Mild V-shaped narrowing of the intervertebral disc space C6/C7 is appreciated. Post intrathecal contrast administration, the intervertebral disc space C6/C7 is mild to moderately protruding into the vertebral canal, distorting the ventral subarachnoid space at the same level.

Level with C1 and C2, the contrast media in the subarachnoid space is pooling in the gravity dependent ventral aspects – resulting in a non-contrast enhanced dorsal segment of the subarachnoid space.

COMPUTED TOMOGRAPHIC DIAGNOSIS

- Mild intervertebral disc protrusion C6/C7 with possible dynamic spinal cord compression

INTERPRETATION OF THE FINDINGS & FURTHER RECOMMENDATIONS

The intervertebral disc protrusion C6/C7 can be a source for intermittent pain but is unlikely to cause neurological deficits. No additional abnormalities of the cervical spine are appreciated – depending on the presenting clinical signs, rule out pathology of the thoracic & lumbar spine as well.



PATIENT

Skeeter Swenson

SPECIES

Canine

BREED

Springer Spaniel

SEX

Male Neutered

AGE

8 Years

INTERPRETED BY

Sebastian Schaub, DVM
Dr. med. vet. DipECVDI

HOSPITAL NAME

State Avenue Vet
Clinic

REFERRING VET

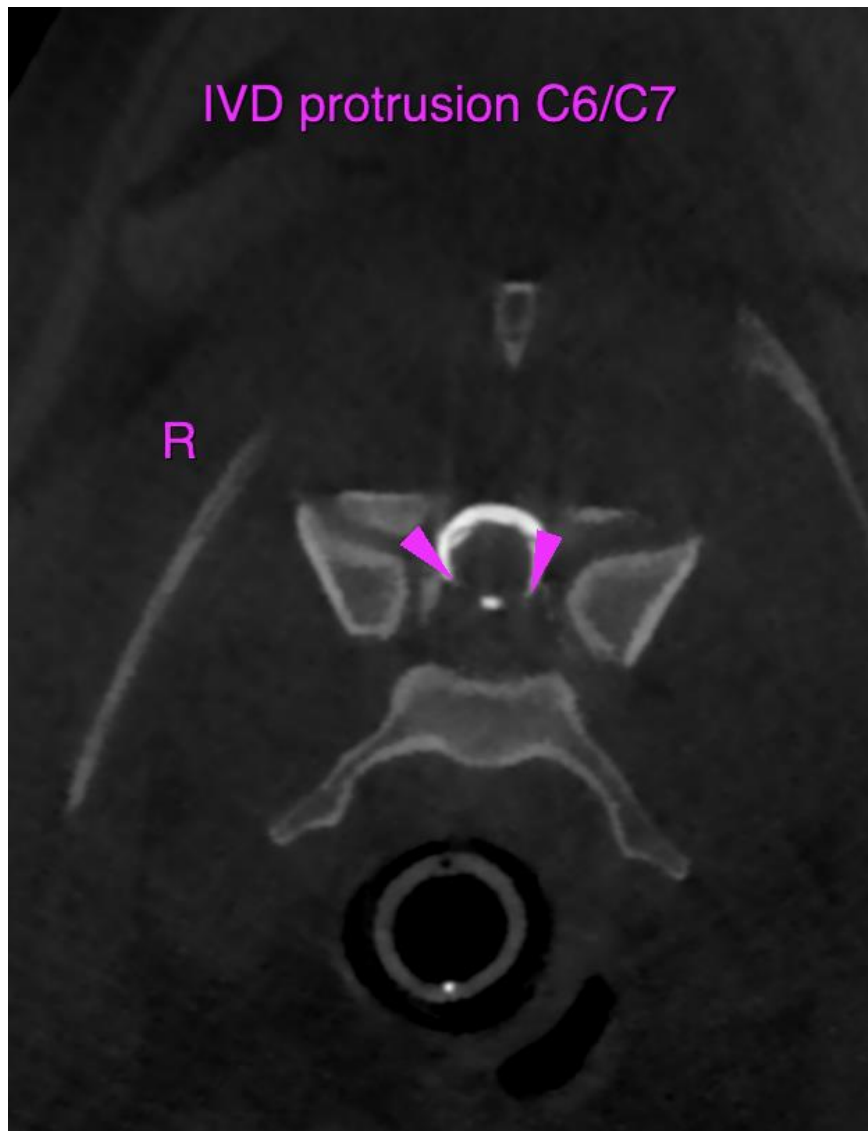
Dr. Raul Casas-Dolz

INVOICE

51928

DATE

5-4-22





PATIENT

Skeeter Swenson

SPECIES

Canine

BREED

Springer Spaniel

SEX

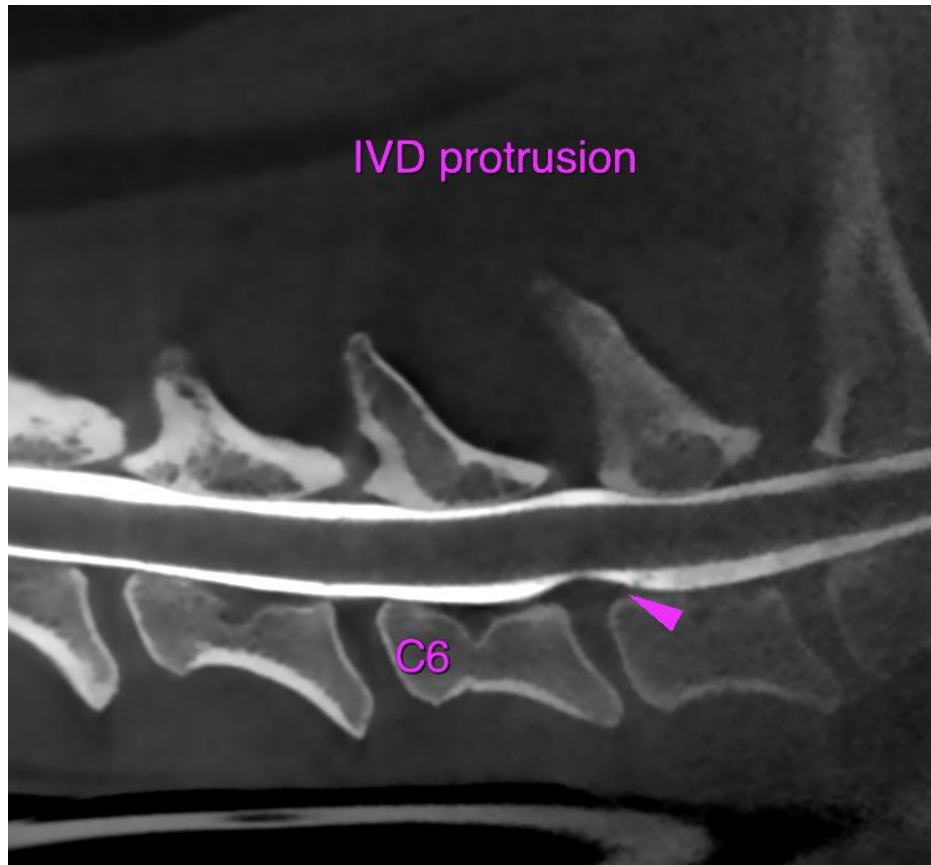
Male Neutered

AGE

8 Years

INTERPRETED BY

Sebastian Schaub, DVM
Dr. med. vet. DipECVDI



HOSPITAL NAME

State Avenue Vet
Clinic

REFERRING VET

Dr. Raul Casas-Dolz

INVOICE

51928

DATE

5-4-22

The information and recommendations provided are based on the images presented by the referring veterinarian/sonographer. No evaluation can be communicated regarding pathology that was not visible in the image/video clips provided.

Thank you for this referral. If the clinical or image interpretation does not parallel your findings or if I can be of any further assistance please contact me.

Sebastian Schaub, Sebastian Schaub, DVM, Dr. med. vet. DipECVDI
sebast.schaub@gmail.com