



**PATIENT PRESENTING CLINICAL SIGNS**

**PATIENT**  
Rocky Collum

**SPECIES**  
Canine

Rocky presents to MVCT for a CT scan of his left shoulder and thorax. A pre- and post- contract study submitted in a bone and soft tissue reconstruction is provided for review. Severe paralysis of left thoracic limb with severe muscle wasting. Reduced deep and superficial pain but painful on manipulation. Onset was progressive duration over 1 year. Attitude changed recently and became aggressive towards owners. History of being treated with steroid and Gabapentin. Abnormal PE/Chem/CBC/UA Results: Radiograph of thorax indicates possible mediastinal changes. Lab work- elevated BUN 34mg/dL (7-27)

**BREED COMPUTED TOMOGRAPHY OF THE THORAX**

**BREED**  
Boxer

A pre- and post-contrast CT study of the thorax in a bone and soft tissue reconstruction is provided for review.

**COMPUTED TOMOGRAPHIC FINDINGS**

**SEX**  
M

Multifocal mild spondylosis formation is seen along the thoracic spine. The periarticular bones of the right elbow joint present moderate osteophyte new bone formation. The volume of the left triceps muscle is significantly decreased and generalized moderate reduced volume of the left brachial musculature is appreciated. The left spinal nerve T2, level with the second and first left rib is irregularly thickened, measuring up to 2.2 cm in diameter over a length of approximately 4.5-5 cm and presenting an irregular contrast enhancement pattern.

**AGE**  
7

The sternal, cranial mediastinal and tracheobronchial lymph nodes are small elongated with a normal short-to-long-axis-ratio is < 0.5, the attenuation and contrast enhancement pattern is uniform and considered within normal limits.

**INTERPRETED BY**

Sebastian Schaub, DVM  
Dr. med. vet. DipECVDI

The cardiovascular structures including the pulmonary vasculature are within normal limits.

The bronchial tree presents with regular branching and tapers uniformly towards the periphery as expected, the bronchial walls are thin and smooth. The bronchus-to-artery ratio is within normal limits.

**HOSPITAL NAME**

Mobile Veterinary CT

The lung parenchyma presents the expected architecture and attenuation behavior with sporadic interspersed punctuate mineralization.

**REFERRING VET**

Robert Drysdale

Small incidental gas pockets are seen within the esophageal lumen, there is no evidence of abnormal dilation.

**COMPUTED TOMOGRAPHIC DIAGNOSIS**

**INVOICE**

51902

- Segmental neuropathy left spinal nerve T2, less likely T1
- Neurogenic muscle atrophy left triceps muscle
- Degenerative osteoarthritis right elbow joint – suspect underlying coronoid pathology
- Pulmonary osteomas
- No evidence of pulmonary metastatic disease

**DATE**

5-4-22

**INTERPRETATION OF THE FINDINGS & FURTHER RECOMMENDATIONS**

The findings are consistent with malignant peripheral nerve sheath tumor of the left spinal nerve T2 or less likely T1. The finding is explaining the presenting clinical signs. The options of palliative management or surgical management with amputation of the respective limb and resection of the



**PATIENT**

Rocky Collum

thickened spinal nerve are potential treatment options. I cannot appreciate, that the thickened spinal nerve is extending up into the spinal canal.

**SPECIES**

Canine

**BREED**

Boxer

**SEX**

M

**AGE**

7

**INTERPRETED BY**

Sebastian Schaub, DVM  
Dr. med. vet. DipECVDI

**HOSPITAL NAME**

Mobile Veterinary CT

**REFERRING VET**

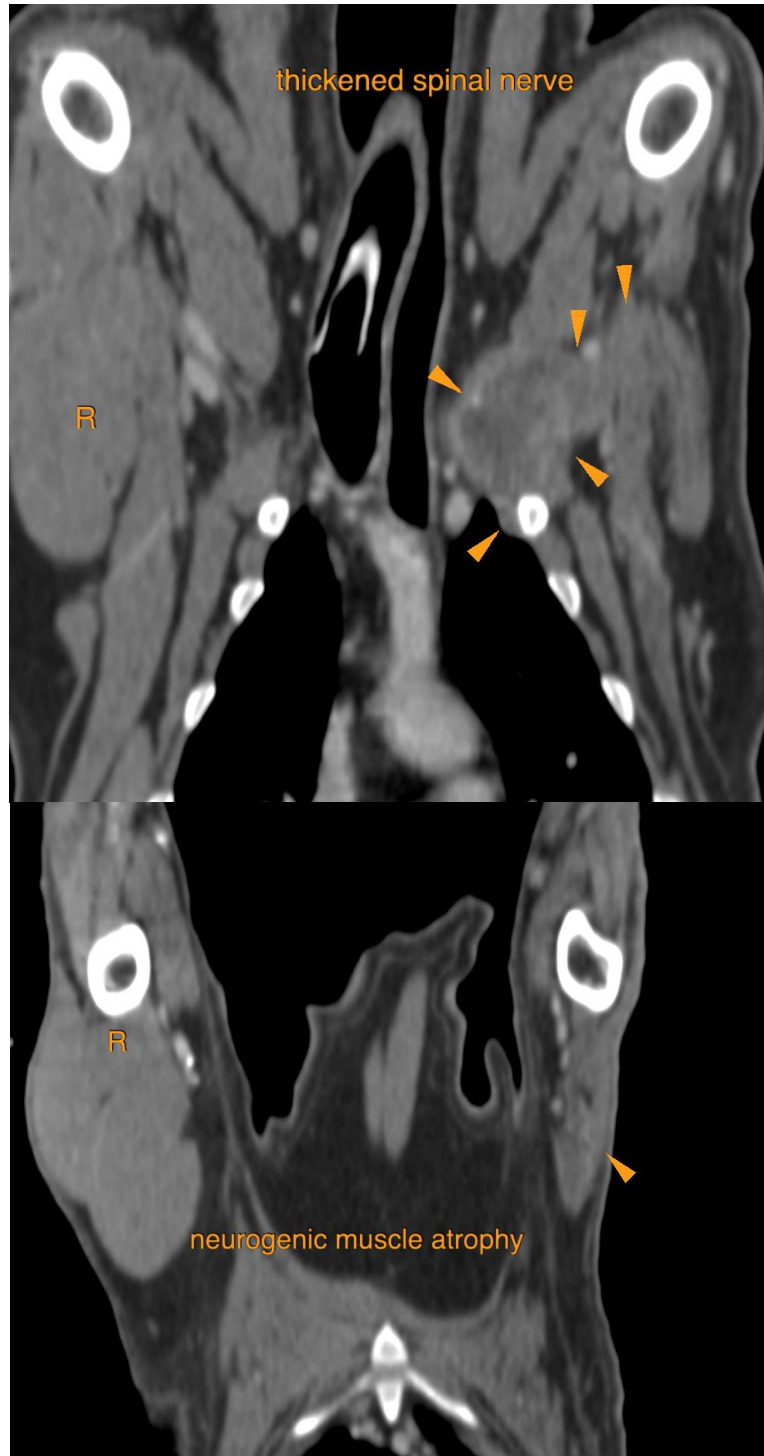Robert Drysdale

**INVOICE**

51902

**DATE**

5-4-22





**PATIENT**

Rocky Collum

**SPECIES**

Canine

**BREED**

Boxer

**SEX**

M

**AGE**

7

**INTERPRETED BY**

Sebastian Schaub, DVM  
Dr. med. vet. DipECVDI

**HOSPITAL NAME**

Mobile Veterinary CT

**REFERRING VET**

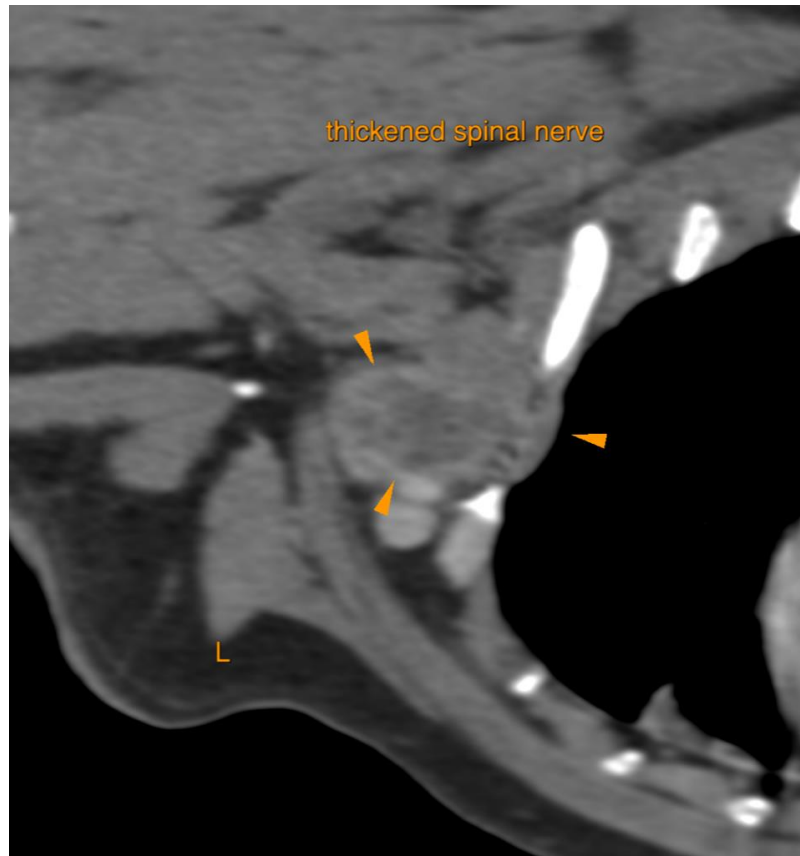
Robert Drysdale

**INVOICE**

51902

**DATE**

5-4-22



The information and recommendations provided are based on the images presented by the referring veterinarian/sonographer. No evaluation can be communicated regarding pathology that was not visible in the image/video clips provided.

Thank you for this referral. If the clinical or image interpretation does not parallel your findings or if I can be of any further assistance please contact me.

**Sebastian Schaub**, Sebastian Schaub, DVM, Dr. med. vet. DipECVDI  
sebast.schaub@gmail.com