



PATIENT PRESENTING CLINICAL SIGNS

Janet Mcfarlane History: presented for standard cohat
Abnormal PE/Chem/CBC/UA Results:

SPECIES COMPUTED TOMOGRAPHIC STUDY OF THE SKULL

Canine A high resolution pre- and post-contrast CT study of the skull is provided for review.

COMPUTED TOMOGRAPHIC FINDINGS

BREED

Terrier

Triadan 101-103, 105, 108, 201, 202, 205, 206, 208, 301-303 and 401-403 are absent. Triadan 203 presents a moderate widening of the periodontal space. A generalized mild horizontal bone loss is present in all jaw quadrants.

SEX

Neutered Male

The nasal cavity presents the expected aerated spaces between thin & even conchae and turbinates with smooth mucosal lining.

AGE

11 Years

Both temporomandibular joints present congruent joint spaces with even subchondral bone surfaces and are considered within normal limits.

Both tympanic bullae are aerated, the mucosal lining is not seen, the bony wall is smooth and thin. The external ear canals are within normal limits.

INTERPRETED BY

Sebastian Schaub,
DVM Dr. med. vet.
DipECVDI

COMPUTED TOMOGRAPHIC DIAGNOSIS

- Moderate periodontal disease 203
- Generalized mild horizontal bone loss in all jaw quadrants
- Triadan 101-103, 105, 108, 201, 202, 205, 206, 208, 301-303 and 401-403

HOSPITAL NAME

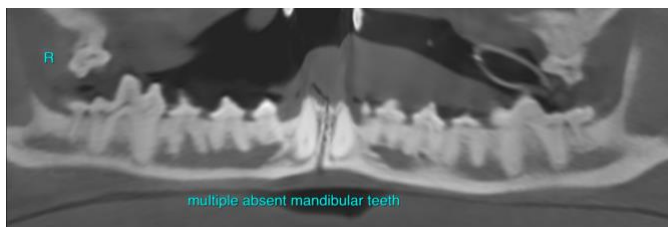
South Bay Ah & PR

INTERPRETATION OF THE FINDINGS & FURTHER RECOMMENDATIONS

Triadan 203 presents with evidence of moderate periodontal disease. The remainder of the dentition present without signs of significant periodontal disease.

REFERRING VET

Dr. Ravinder Atwal



INVOICE

15084

DATE

5/4/22



PATIENT

Janet Mcfarlane

SPECIES

Canine

BREED

Terrier

SEX

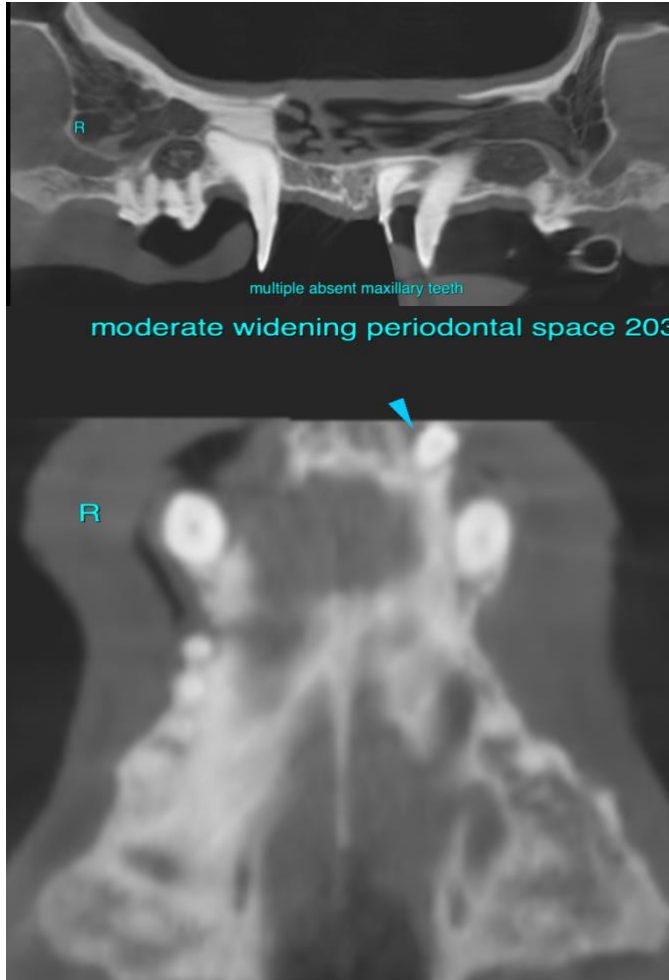
Neutered Male

AGE

11 Years

INTERPRETED BY

Sebastian Schaub,
DVM Dr. med. vet.
DipECVDI



HOSPITAL NAME

South Bay Ah & PR

The information and recommendations provided are based on the images presented by the referring veterinarian/sonographer. No evaluation can be communicated regarding pathology that was not visible in the image/video clips provided.

REFERRING VET

Dr. Ravinder Atwal

Thank you for this referral. If the clinical or image interpretation does not parallel your findings or if I can be of any further assistance please contact me.

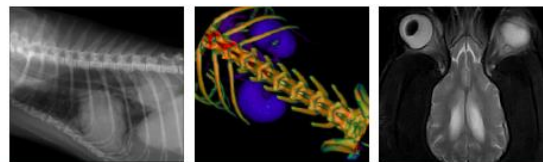
INVOICE

15084

DATE

5/4/22

Sebastian Schaub, Sebastian Schaub, DVM, Dr. med. vet. DipECVDI
sebast.schaub@gmail.com



PATIENT

Janet Mcfarlane

SPECIES

Canine

BREED

Terrier

SEX

Neutered Male

AGE

11 Years

INTERPRETED BY

Sebastian Schaub,
DVM Dr. med. vet.
DipECVDI

HOSPITAL NAME

South Bay Ah & PR

REFERRING VET

Dr. Ravinder Atwal

INVOICE

15084

DATE

5/4/22