



PATIENT

Jackson Wright

PRESENTING CLINICAL SIGNS

exam for lameness, lab work reveals hypercalcemia
Abnormal PE/Chem/CBC/UA Results: , lab work reveals 12.6 unfasted then 12.8 fasted calcium mg/dL

SPECIES

Canine

RADIOGRAPHIC STUDY OF THE THORAX&ABDOMEN

A complete set of radiographs of the thorax and abdomen is provided for review.

BREED

Rhodesian Ridgeback
Mix

RADIOGRAPHIC FINDINGS

Thorax

The costal cartilages present moderate degenerative changes.

The extrathoracic soft tissues present homogeneous without abnormalities.

The heart is of normal size and shape, there is no evidence of cardiac chamber or vascular enlargement. The pulmonary vasculature is within normal limits.

SEX

MN

The cranial mediastinum presents the expected soft tissue opacity. The mediastinal width is less than twice the width of the vertebral column at the same level.

AGE

10 Years

The trachea is normal in diameter and presents the anticipated course. The luminal outline of the trachea is smooth.

INTERPRETED BY

Sebastian Schaub, DVM
Dr. med. vet. DipECVDI

The bronchial tree presents with thin walls and tapers uniformly towards the periphery as expected.

The lung parenchyma presents a generalized moderate unstructured reticular pattern, blurring the peripheral lung vessels.

The diaphragm is well delineated with even surface and the expected mild cranial bulging of the diaphragmatic cupola.

HOSPITAL NAME

Northshore
Veterinary Hospital

Abdomen

The vertebral endplates L1/L2 present mild spondylosis formation. Multiple facet joints along the lumbar spine show moderate osteophyte new bone formation.

REFERRING VET

Brita Kiffney

No abnormalities of the extraabdominal soft tissues are noted. The abdominal wall is smooth and thin.

The serosal detail is maintained throughout the peritoneal and retroperitoneal space.

INVOICE

51901

The hepatic volume is moderately increased the liver is protruding beyond the costal arch. The caudoventral hepatic margins are mildly rounded.

The splenic head is in the anticipated position and within normal limits for size and opacity. The splenic body and tail are considered normal for position, size, shape and opacity.

DATE

5-4-22

Both kidneys are seen and present with normal size, shape, delineation and opacity. The urinary bladder is in its anticipated position. No radiopaque calculi are noted throughout the upper and lower urinary tract.



PATIENT

The stomach is in its anticipated position and presents normal content.

Jackson Wright

The small intestinal loops are of even diameter and non-dilated, a small amount of gas is seen within the small intestinal loops and considered within normal limits.

SPECIES

The colon is seen in the expected position and presents with appropriate content.

Canine

BREED

Rhodesian Ridgeback
Mix

RADIOGRAPHIC DIAGNOSIS

- Mild hepatomegaly
- Mild to moderate unstructured interstitial lung pattern
- Serial spondylarthrosis lumbar spine
- Spondylosis deformans

INTERPRETATION OF THE FINDINGS & FURTHER RECOMMENDATIONS

No pathology for the hypercalcemia can be appreciated. Rule out primary hypercalcemia (e.g. adenoma parathyroid gland) or paraneoplastic causes (e.g. round cell tumor, anal sac adenocarcinoma).

SEX

MN

Potentials for the hepatomegaly include metabolic hepatic disease/steroid induced hepatopathy, hepatitis or neoplastic infiltration. Ultrasound including FNA sampling can be used as minimally advanced diagnostic tests.

AGE

10 Years

The unstructured interstitial lung pattern is likely a sequela to age related changes of the lung parenchyma. The odds for 'real' interstitial lung pattern are considered low, non specific differentials include fibrosis, pneumonitis (inflammatory versus infectious), systemic disease (e.g. pancreatitis, IMHA, renal disease), neoplasia.

INTERPRETED BY

Sebastian Schaub, DVM
Dr. med. vet. DipECVDI

HOSPITAL NAME

Northshore
Veterinary Hospital

REFERRING VET

Brita Kiffney

INVOICE

51901

DATE

5-4-22



PATIENT

Jackson Wright

SPECIES

Canine

BREED

Rhodesian Ridgeback
Mix

SEX

MN

AGE

10 Years

INTERPRETED BY

Sebastian Schaub, DVM
Dr. med. vet. DipECVDI

HOSPITAL NAME

Northshore
Veterinary Hospital

REFERRING VET

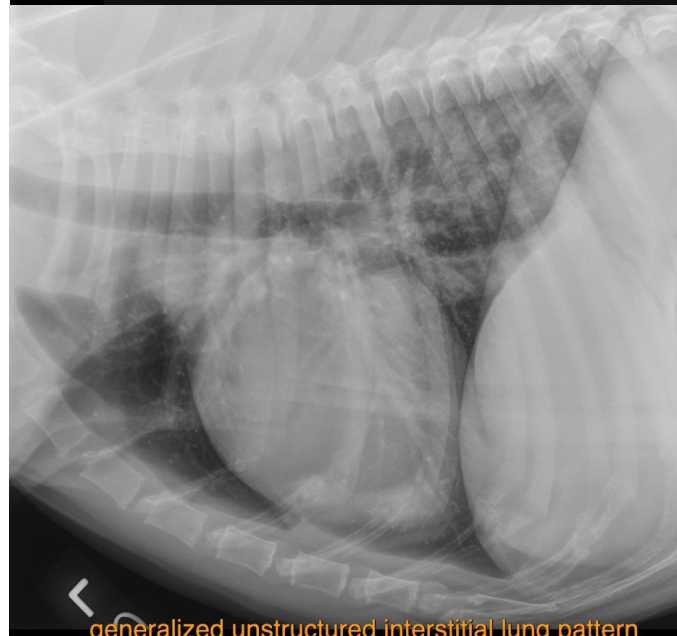
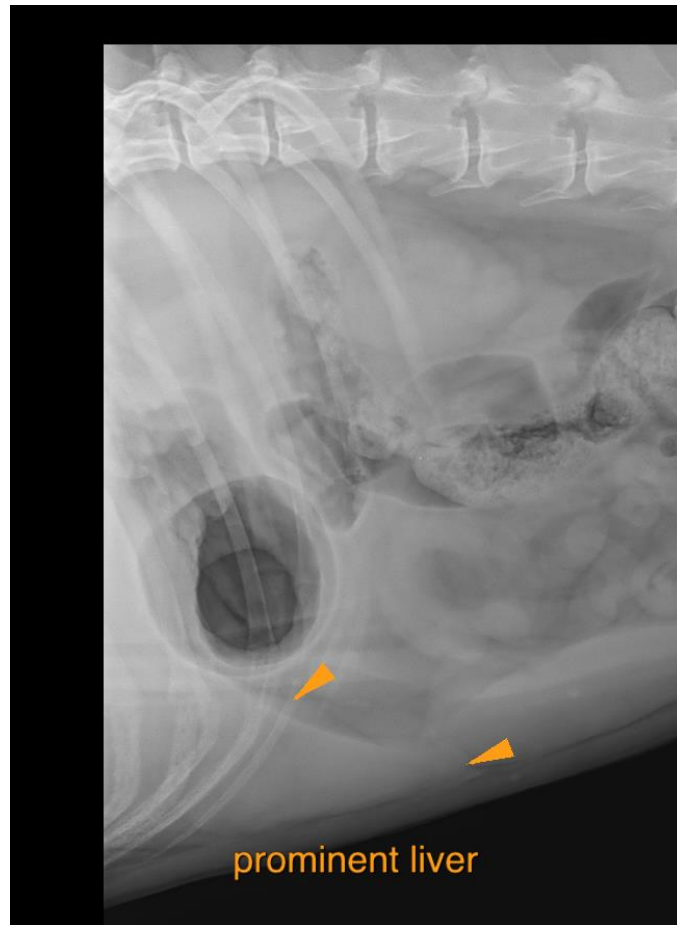
Brita Kiffney

INVOICE

51901

DATE

5-4-22





PATIENT

Jackson Wright

SPECIES

Canine

BREED

Rhodesian Ridgeback
Mix

SEX

MN

AGE

10 Years

INTERPRETED BY

Sebastian Schaub, DVM
Dr. med. vet. DipECVDI

HOSPITAL NAME

Northshore
Veterinary Hospital

REFERRING VET

Brita Kiffney

INVOICE

51901

DATE

5-4-22

The information and recommendations provided are based on the images presented by the referring veterinarian/sonographer. No evaluation can be communicated regarding pathology that was not visible in the image/video clips provided.

Thank you for this referral. If the clinical or image interpretation does not parallel your findings or if I can be of any further assistance please contact me.

Sebastian Schaub, Sebastian Schaub, DVM, Dr. med. vet. DipECVDI
sebast.schaub@gmail.com