



**PATIENT PRESENTING CLINICAL SIGNS**

Isabelle Connel History: pt fractured 208 from chewing, extracted.  
Abnormal PE/Chem/CBC/UA Results:

**SPECIES COMPUTED TOMOGRAPHIC STUDY OF THE SKULL**

Canine A high-resolution plain CT study of the skull is provided for review.

**COMPUTED TOMOGRAPHIC FINDINGS**

**BREED**

Labradoodle

The tooth elements 308 and 408 are absent. Triadan 208 presents a lamellar fracture of the buccal surface of the crown, exposing the pulp cavity to the surface. The remainder of the dentition present no abnormalities.

**SEX**

Spayed Female

The nasal cavity presents the expected aerated spaces between thin & even conchae and turbinates with smooth mucosal lining.

**COMPUTED TOMOGRAPHIC DIAGNOSIS**

**AGE**

2 Years

- Complicated lamellar fracture of triadan 208
- Absent triadan 308 and 408

**INTERPRETATION OF THE FINDINGS & FURTHER RECOMMENDATIONS**

**INTERPRETED BY**

Sebastian Schaub,  
DVM Dr. med. vet.  
DipECVDI

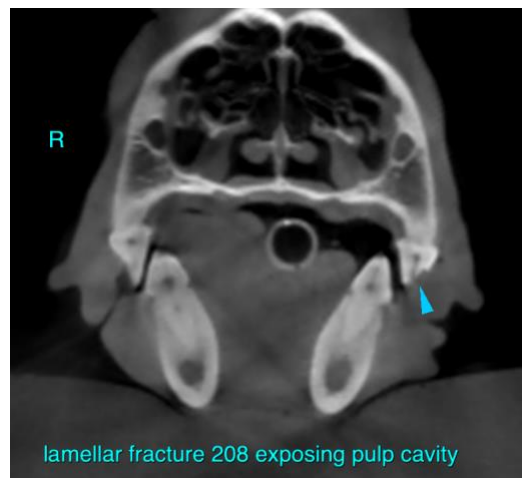
The fractured crown of triadan 208 is exposing the pulp cavity to the surface, potentially predisposing for development of dental abscess. The remainder of the dentition are within normal limits.

**HOSPITAL NAME**

South Bay AH & PR

**REFERRING VET**

Dr. Ravinder Atwal



lamellar fracture 208 exposing pulp cavity

**INVOICE**

15085

**The information and recommendations provided are based on the images presented by the referring veterinarian/sonographer. No evaluation can be communicated regarding pathology that was not visible in the image/video clips provided.**

**DATE**

5/4/22



**PATIENT**

Isabelle Connel

Thank you for this referral. If the clinical or image interpretation does not parallel your findings or if I can be of any further assistance please contact me.

**SPECIES**

Canine

**Sebastian Schaub**, Sebastian Schaub, DVM, Dr. med. vet. DipECVDI  
sebast.schaub@gmail.com

**BREED**

Labradoodle

**SEX**

Spayed Female

**AGE**

2 Years

**INTERPRETED BY**

Sebastian Schaub,  
DVM Dr. med. vet.  
DipECVDI

**HOSPITAL NAME**

South Bay AH & PR

**REFERRING VET**

Dr. Ravinder Atwal

**INVOICE**

15085

**DATE**

5/4/22